

**Abstract:**

Ocular trauma is common in children, occurring from a variety of mechanisms in recreation and athletics. Differentiating simple eye injuries from those requiring urgent or emergent ophthalmologic evaluation is critical in acute care settings such as emergency departments and urgent care centers. A thorough eye examination is key to the diagnosis of nonpenetrating eye trauma, and a high index of suspicion should be maintained for any patient complaining of visual deficits or ocular pain. Although most eye injuries are minor, early ophthalmology consultation or referral should be considered for select injuries. This article details the approach to acute nonpenetrating eye trauma in children, featuring the most common injuries to the cornea, anterior chamber, posterior segment, and orbit.

**Keywords:**

pediatric; ophthalmologic trauma; traumatic hyphema; corneal abrasions; ocular burns; orbital fractures; traumatic iritis; traumatic uveitis

\*Emergency Medicine and Trauma Services, Children's National Medical Center, Washington, DC; †Castillejos Eye Institute, Chula Vista, CA; ‡Department of Pediatrics, Division of Emergency Medicine, Columbia University College of Physicians and Surgeons, New York, NY.

Reprint requests and correspondence: Jeremy M Root, MD, Division of Emergency Medicine, Children's National Medical Center, 111 Michigan Ave, NW, Washington, DC 20010.

[jroot@childrensnational.org](mailto:jroot@childrensnational.org)

1522-8401

© 2017 Elsevier Inc. All rights reserved.

# Nonpenetrating Eye Injuries in Children

**Jeremy M. Root, MD\*, Shipra Gupta, MD†, Nazreen Jamal, MD‡**

**E**ye trauma is a common occurrence in the pediatric population, with an estimated 840 000 annual injuries in the United States.<sup>1,2</sup> Although the emergency department (ED) has traditionally been the site for evaluation of acute ocular injury, most pediatric eye injuries are minor and can be evaluated by qualified providers in urgent and ambulatory care settings, especially in the absence of obvious penetrating injury or globe rupture. Despite the prevalence of injury in both recreation and athletics, most eye injuries can be prevented with improved safety precautions,<sup>1,3</sup> and few injuries require emergent management. Frontline providers require the skills to recognize signs of more serious injury that can be potentially vision saving. This article describes the evaluation and management of routine eye injuries in the pediatric population, featuring the most common nonpenetrating injuries including corneal abrasions, ocular burns, traumatic hyphemas, orbital fractures, uveitis, iritis, and posterior segment injuries.

## EVALUATION

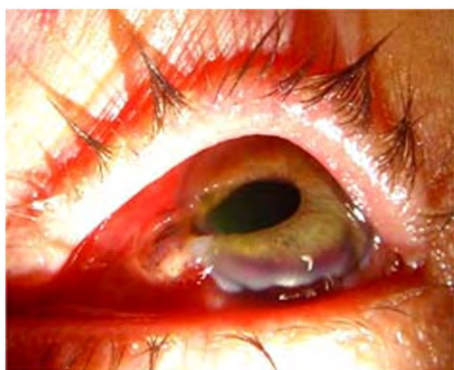There are 4 guiding principles in the assessment of ophthalmologic trauma: (1) manage (other) life-threatening injuries, (2) ensure the structural integrity of the globe, (3) assess vision in the injured and uninjured eye, and (4) seek ophthalmology consultation when further assistance is needed.<sup>4</sup> Assessment of pediatric ocular trauma is further complicated by the special needs of the pediatric population. If available, child life specialists should be employed to aid in the examination of the young patient. Physicians should be careful to minimize unnecessary distress, as crying can increase ocular pressure and lead to extrusion of intraocular contents.<sup>4</sup>

**TABLE 1. Stepwise approach to ocular trauma.**

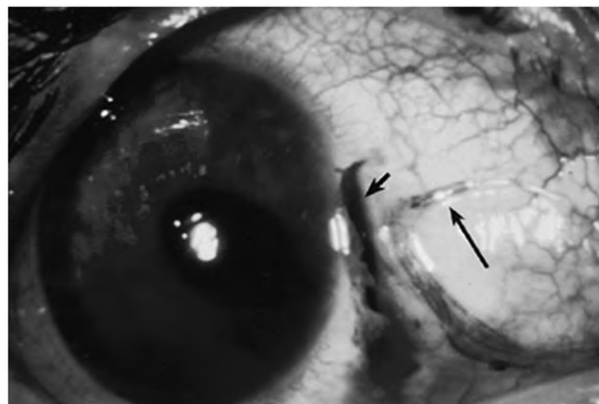
1. Assess light perception in both injured and uninjured eye. If a child has trouble with letters, a matching or picture chart can be used.
2. Assess visual acuity in both injured and uninjured eye
3. Inspect periorbital and eyelids tissues for bruising, lacerations, and ptosis.
4. Examine movements of ocular muscles.
5. Evaluate anterior surface of the eye.
6. Rule out ruptured globe.
7. Consider use of pharmacologic agents to dilate pupils.
8. Examine for red reflex.
9. Direct ophthalmoscopy to assess for papilledema or retinal hemorrhages.

Data from Levin.<sup>4</sup>

The evaluation of the acutely injured eye should begin with assessment of visual acuity (Table 1). If the patient cannot open the injured eye because of pain or swelling, the physician can shine a bright penlight into the affected eye to evaluate light perception. In nonverbal patients, careful attention should be paid to reflex contraction of the eyelid that confirms light perception.<sup>4</sup> If the patient can open the eye, visual acuity can be assessed by counting fingers or using commercially available age-appropriate vision cards. If a patient exhibits poor vision in the traumatized eye, uncorrected refractive errors can be differentiated from trauma-related visual impairment by rechecking vision while having the patient look through a pinhole.<sup>4</sup> After assessing visual acuity, the periorbital tissues and eyelids should be evaluated for ptosis,



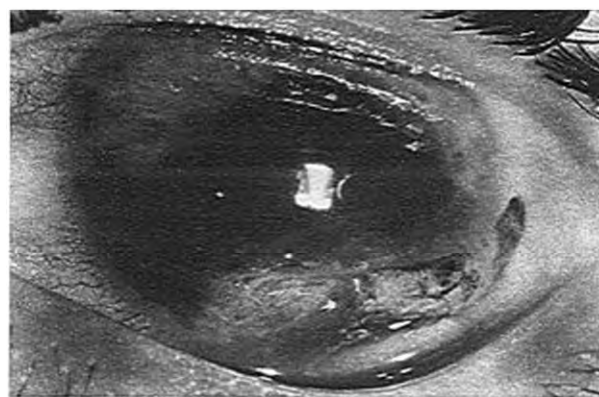
**Figure 1.** Ruptured globe. Notice the choroid material plugging the wound. Courtesy of Gerstenblith and Rabinowitz.<sup>8</sup>



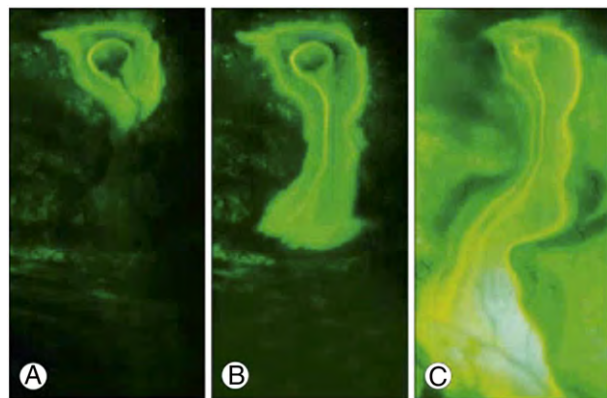
**Figure 2.** Ruptured globe. The short arrows shows a linear line on the sclera from iris or choroid plugging due to globe injury. Courtesy of Levin.<sup>4</sup>

ecchymosis, and lacerations, followed by an assessment of the eye muscles.

Prior to pharmacologic dilation of the eye, the practitioner must ensure that there is no evidence of a ruptured (open) globe, which can occur following trauma to the eye from projectiles, sharp objects, or blunt trauma.<sup>4</sup> Typical ruptured globes appear as blue, brown, or black material on the surface of the eye as the iris or choroid plugs the wound (Figure 1). There may be protrusion of the iris at the corneoscleral junction, and the pupil can take on a teardrop shape (Figures 2 and 3). Although subconjunctival hemorrhage is common in blunt eye injury, circumferential hemorrhage and bullous hemorrhage are both suspicious for perforation. The eyeball does not deflate with small lacerations and often maintains normal contour, so an open or ruptured globe may be subtle.<sup>4</sup> In suspect cases, providers can perform a Seidel test using fluorescein dye. In the presence of an open globe,



**Figure 3.** Ruptured globe. Note the disruption of the anterior chamber and lens and the tear drop shape of the pupil, classic for globe injury. Courtesy of Navon.<sup>55</sup>



**Figure 4.** The Seidel test. A, The fluorescein is applied directly to the injured site demonstrating leakage of aqueous through a perforated cornea. B and C, Progression of the dynamic flow of aqueous. Courtesy of Martonyi and Maio.<sup>6</sup>

a stream of aqueous dilutes the fluorescein as it streams down the eye (Figure 4).<sup>5,6</sup>

Once the possibility of a ruptured globe has been ruled out, the use of phenylephrine 2.5% or tropicamide 1% can be considered to dilate the pupil.<sup>4</sup> The posterior eye should be carefully evaluated for papilledema and retinal hemorrhages by direct ophthalmoscopy. Topical anesthetics and the use of ocular speculums may become necessary if the patient is unable to voluntarily open the eye because of trauma and swelling.<sup>4</sup> Although the trauma history will often direct the differential diagnosis, a complete ocular examination is imperative in differentiating ocular urgencies from emergencies (Table 2).<sup>4</sup>

## CORNEAL ABRASIONS

Eye contusions and abrasions comprise almost half of eye injury visits to US EDs.<sup>3</sup> A corneal abrasion is a defect in the epithelial surface of the cornea. Because the cornea is the most anterior part of the eye, it is often injured in blunt ocular trauma.<sup>7</sup> Corneal

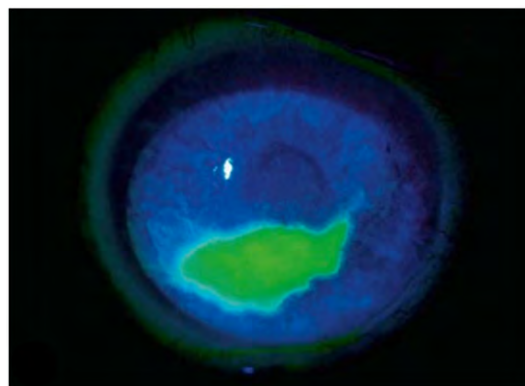
abrasions can also occur from foreign bodies, contact lens use, and chemical burns.

Patients with corneal abrasions classically present with severe, sharp eye pain; photophobia; foreign body sensation; and discomfort with blinking and tearing after a history of eye trauma.<sup>4,7,8</sup> If the ocular examination demonstrates additional injury such as corneal infiltrates, pus in the anterior chamber (hypopyon), signs of traumatic iritis including ciliary spasm, and irregular or fixed pupils, prompt consultation with ophthalmology is recommended.<sup>7</sup>

Corneal abrasions are diagnosed by direct visualization with a Woods lamp examination after fluorescein application (Figure 5). Larger defects can sometimes be visualized without fluorescein (Figure 6). A drop of proparacaine 0.5% can be applied directly onto the eye or onto a fluorescein strip to minimize pain during the examination. Traumatic corneal abrasions typically have linear or geographic shapes. Contact lens use can result in lesions that coalesce around a central defect.<sup>4,7</sup> Multiple vertical lines on the superior cornea suggest a foreign body under the upper lid and should prompt eversion of the upper eyelid. The upper eyelid can be rotated over a cotton swab to assist with inspection.<sup>4,5,7</sup> (Figure 7).

The goals of corneal abrasion management include relieving pain, preventing infection, and accelerating healing. To relieve pain and/or discomfort from accommodation, traditional options include topical nonsteroidal anti-inflammatory drugs (NSAIDs), cycloplegics, anesthetics, and eye patching, although some of these options have fallen out of favor in recent years.

Topical NSAIDs were previously thought to be associated with corneal toxicity, also known as *corneal melting*. However, multiple studies (including a meta-analysis) have supported the use of topical



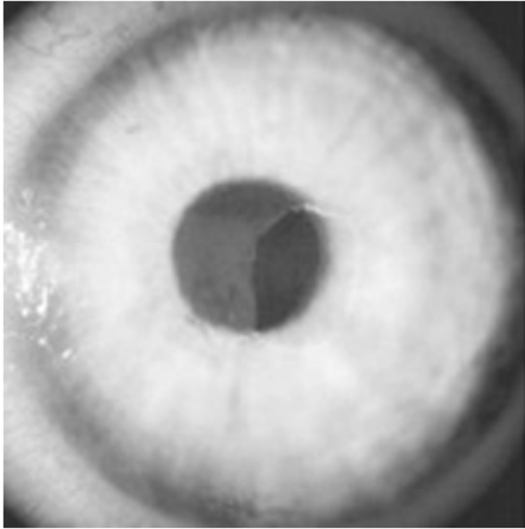
**Figure 5.** Large corneal abrasion stained with fluorescein. Courtesy of Bowling.<sup>56</sup>

**TABLE 2. Acute ophthalmic conditions.**

Emergency	Very Urgent	Urgent
Alkali burns	Globe perforation Globe rupture	Corneal abrasion Corneal ulcer Traumatic hyphema Intraocular foreign body Orbital fractures Retinal detachment

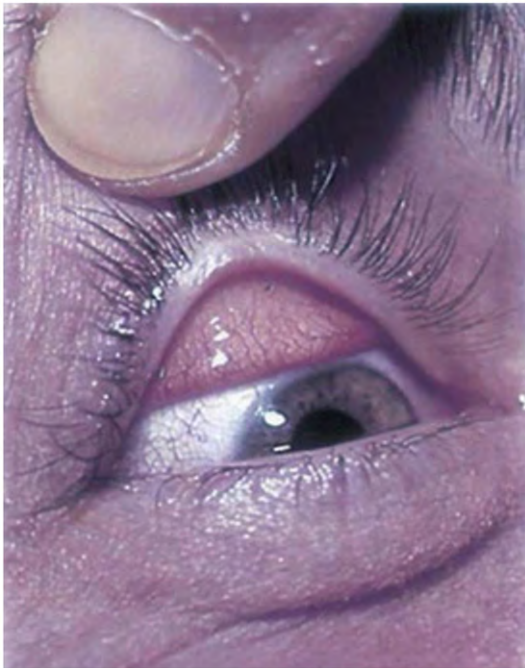Data from Naradzay and Barish.<sup>5</sup>





**Figure 6.** Epithelial defect without fluorescein. There is irregularity in the normally smooth corneal surface. Courtesy of Hoffman.<sup>57</sup>

NSAIDs (such as diclofenac 0.1% and ketorolac 0.4%) for pain relief in adults, reducing the need for oral pain medications and decreasing the time to return to work.<sup>9,10</sup> Because of the possibility of corneal melting and the high cost of these medications, it is currently recommended to limit the use of topical NSAIDs to 2 days. Furthermore, these drugs should be used with particular caution in children



**Figure 7.** Foreign body present on eversion of upper eyelid. Courtesy of Ahmed et al.<sup>58</sup>

because their safety and efficacy have not been well studied in the pediatric population.<sup>4,7,11</sup>

Topical cycloplegics and mydriatics have been used to relax accommodation and provide pain relief in more severe corneal abrasions, but their use has limited benefit in uncomplicated injuries.<sup>7,12</sup> For patients in significant pain, a drop of cyclopentolate 1% can be instilled to relieve ciliary muscle spasms of the eye.<sup>4</sup> These topical medications may also help symptoms related to traumatic iritis that may develop 24 to 72 hours after injury (see section on “Subacute Presentations”).<sup>8</sup>

Topical anesthetics are a helpful adjunct for treating ocular pain and for facilitating the eye examination in patients who are resistant to opening their eyes because of corneal abrasions. One drop of 0.5% proparacaine or 0.5% tetracaine is instilled into the affected eye; onset of action is typically within 20 seconds and lasts for approximately 20 minutes. Despite the effectiveness of topical anesthetics, outpatient use is not typically recommended given concerns of toxicity to the corneal epithelium with repeated administration and delays in wound healing, and the potential to mask worsening symptoms.<sup>7</sup>

Although eye patching for corneal abrasions was previously a common practice, patching is no longer recommended for small, uncomplicated corneal abrasions (typically less than 4 mm). A Cochrane review found that patching of the affected eye does not improve pain and can slow healing while causing temporary loss of binocular vision while wearing a patch.<sup>7,13</sup> However, patching may be indicated for pain control in patients with large corneal abrasions (>50% of the cornea) and for pediatric patients who may continue to rub their eyes without barrier protection.<sup>7</sup>

The utility for infection prophylaxis with topical antibiotics remains controversial. Although there is a lack of evidence demonstrating effectiveness,<sup>14,15</sup> many practitioners routinely prescribe topical antibiotics to prevent superinfection of corneal abrasions.<sup>4,7</sup> Many physicians prefer lubricating antibiotic ointment, such as erythromycin 0.5% ophthalmic, which functions as a lubricant to reduce disruption of the newly generated epithelium. Ointments with neomycin and steroids should be avoided because of risk of creating contact hypersensitivity and susceptibility to infection, respectively.<sup>4,7</sup>

Patients who wear contact lenses, however, may be colonized with *Pseudomonas aeruginosa* and are at risk of rapid progression from a simple corneal abrasion to corneal perforation and vision loss. Therefore, they should be empirically treated with topical antibiotics that cover these organisms, such

as ciprofloxacin 0.3% ointment (or drops).<sup>7,8</sup> For better gram-positive coverage, both moxifloxacin and gatifloxacin performed as well as standard therapy and potentially better than ciprofloxacin in several randomized control trials.<sup>16-20</sup> Combination fortified-antibiotic therapy, such as topical vancomycin and tobramycin, is an alternative to consider for severe infection or eyes unresponsive to initial treatment.<sup>21,22</sup> Furthermore, patients who wear contact lenses should not be patched, as this can create an environment that predisposes them to bacterial ulceration of the cornea.<sup>4</sup> Contact lens users with corneal abrasions should always follow up with an ophthalmologist and should be instructed not to wear contact lenses in the interim.<sup>8</sup>

Most uncomplicated corneal abrasions heal within 24 to 48 hours. Follow-up is generally reserved for patients with large abrasions (greater than 4 mm), those with contact lens-related abrasions, and those with persistent symptoms after 48 hours.<sup>4,7</sup> Complications of corneal abrasions include bacterial keratitis, corneal ulcers, and traumatic iritis. Corneal abrasions related to agricultural work or infectious materials are at especially high risk of bacterial keratitis. If left untreated, bacterial keratitis can progress to corneal ulcers and potentially permanent vision loss.<sup>7</sup>

## OCULAR BURNS

Ocular burns are estimated to be the third most common ophthalmologic injury, accounting for approximately 10% of eye-related ED visits.<sup>3</sup> Although many chemical ocular injuries are workplace related, the majority of eye injuries occur in the home, placing pediatric patients at risk.<sup>3,23</sup>

Chemical ocular burns are a true ocular emergency, requiring immediate evaluation and treatment in an ED or urgent care to prevent permanent vision loss.<sup>5,23,24</sup> Household cleaning products including drain cleaners, lye, and cosmetic agents are frequent offenders. Alkali substances are generally more dangerous than acidic compounds because of their ability to cause liquefaction necrosis of the cornea and rapidly penetrate into the deeper layers of the surface of the eye and anterior chamber.<sup>5,23-25</sup> Concentrated ammonia and lye are particularly dangerous, causing ocular injury in less than 1 minute and 3 to 5 minutes, respectively.<sup>23</sup> Fortunately, most household cleaning products are dilute and tend to result in chemical irritation rather than true chemical burns.<sup>26</sup>

Although acidic burns tend not to penetrate to the deeper tissue of the eye, they can cause focal tissue injury, including corrosive damage of the cornea.

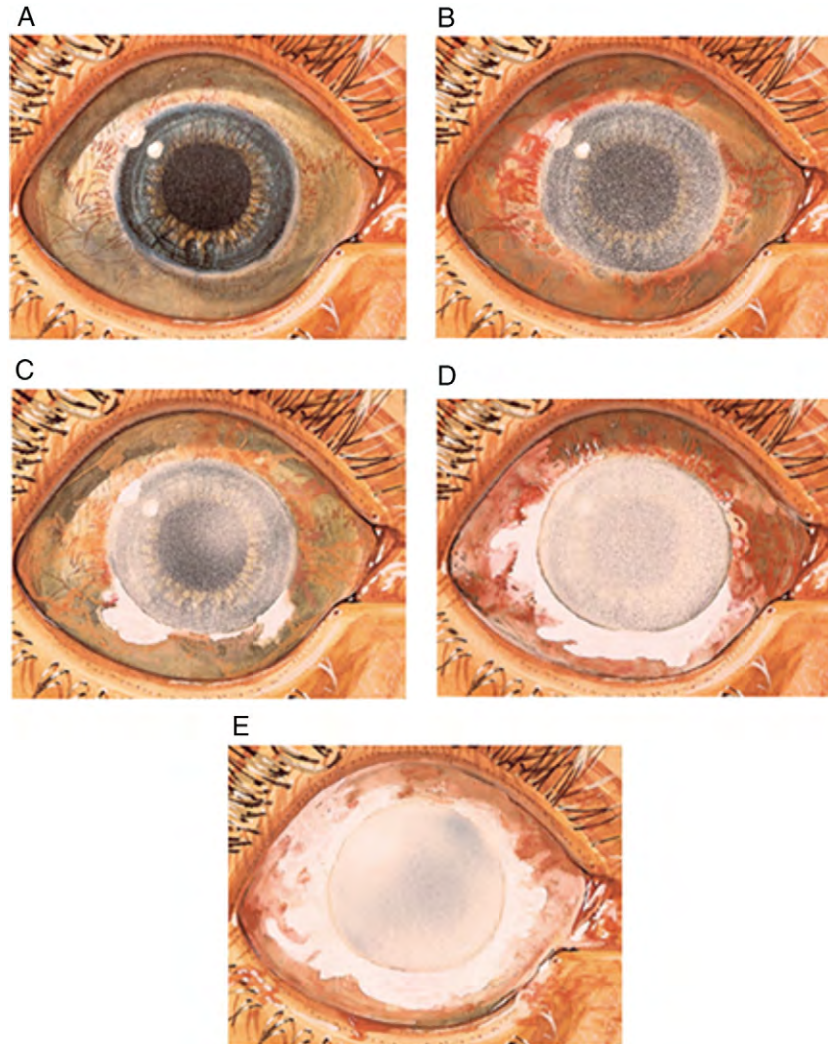
Hydrofluoric acid, found in glass polish and rust removal agents, is especially dangerous with the potential to cause progressive tissue damage and lead to similar outcomes as alkali substances.<sup>23-25,27</sup>

Patients with chemical burns typically present with decreased vision, eye pain, inability to open the eyelids, conjunctival hyperemia, chemosis, and photophobia. The extent of ocular damage is based on time since the exposure to the offending agent. Immediate harm occurs at time of injury, including necrosis of the corneal and conjunctival epithelium and chemical invasion into the anterior chamber (Figure 8). The later phases of the burn occur over days to weeks<sup>23</sup> (Figure 9).

The immediate goals of acute management include pain control and proper irrigation to reduce the risk of scarring, vision deterioration, and permanent loss of vision.<sup>5,28</sup> Early consultation with ophthalmology is recommended for all severe ocular burns; however, ocular irrigation should begin as soon as possible because delays in irrigation can lead to more severe injury. The eye must be irrigated with copious amounts of water, saline, or lactated Ringer's solution until the lacrimation fluid has a normal pH, generally between 6.8 and 7.4.<sup>5,23-25</sup> Any nontoxic solution is effective and appropriate for irrigation.<sup>23</sup> Acidic or basic solutions, however, should be avoided because acid-base reactions can generate harmful substances.<sup>8</sup> If only 1 eye is affected, the unaffected eye can be used to determine the normal ocular pH. There is limited evidence on the optimal duration of eye irrigation for chemical burns, especially in children.<sup>28</sup> Many ophthalmologists recommend continuous irrigation for 30 minutes and then every 15 to 30 minutes until the pH returns to the normal range. The ocular pH should be rechecked 30 minutes after the eye is restored to a normal pH to confirm that the neutral pH is maintained.<sup>23</sup>

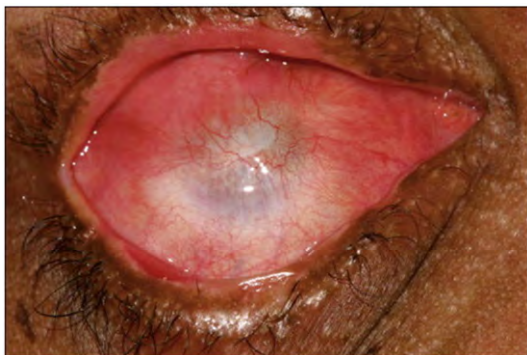Irrigation systems, such as the Morgan Lens, are recommended for prolonged ocular irrigation. The irrigating solution can soothe the eye and also help separate the lid from the cornea.<sup>24</sup> Because both the injury and irrigation systems can be uncomfortable, the use of topical anesthetics, such as 0.5% proparacaine, is recommended for analgesia.<sup>23,24</sup> Ocular irrigation can be particularly challenging in young patients and may require additional sedatives, papoose restraints, and the assistance of a child life specialist to ensure the safety and efficacy of the procedure.

After irrigation is complete, a thorough eye examination is necessary to look for any particulate matter and to evaluate the extent of ocular burn (Figure 7). Special care should be taken to examine the



**Figure 8.** Classification of alkali-burned eye. Courtesy of Pfister and Pfister.<sup>59</sup>

conjunctival fornices and under the upper lids via tarsal eversion for residual particles. Cycloplegic eye drops are indicated for pain relief and prevention of iris



**Figure 9.** Complete corneal vascularization and opacification in a patient with previous alkali injury. Courtesy of Rao and Goldstein.<sup>60</sup>

adhesion to the cornea and lens. Most sources recommend treatment with topical antibiotic ointment such as erythromycin or tetracycline following an ocular burn.<sup>23-25,29</sup> The use of steroids and more novel therapies such as topical ascorbate or citrate should be reserved for an ophthalmologist.<sup>5,23,24,29</sup> Close ophthalmologic follow-up is essential for all patients with ocular burns of any severity.<sup>5,23,24</sup>

## TRAUMATIC HYPHEMA

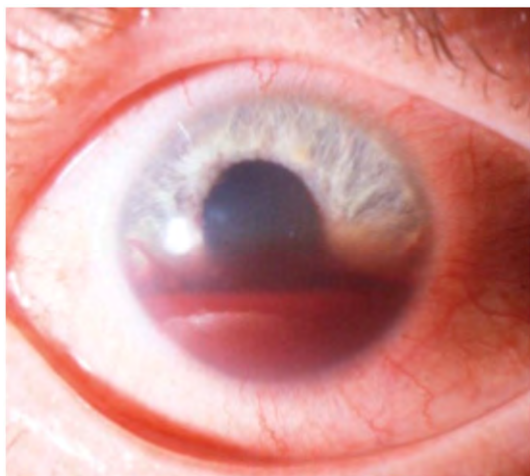
Traumatic hyphema is a sign of severe ocular trauma caused by blunt trauma to the orbit with resultant entry of blood into the anterior chamber, the space between the cornea and iris. More than half of traumatic hyphemas are sports related.<sup>30,31</sup> Hyphemas are at risk for secondary hemorrhage, or rebleeding into the anterior chamber, which



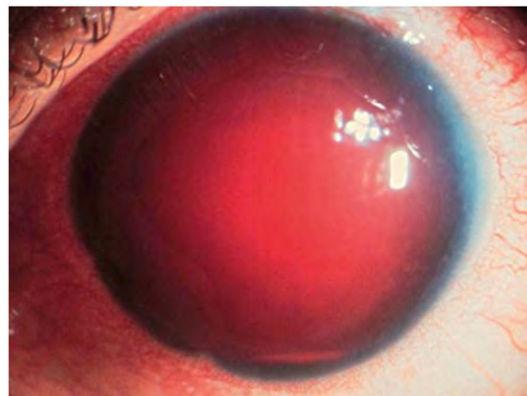typically occurs 2 to 7 days after the initial injury and indicates a poor prognosis.<sup>30</sup>

Most hyphemas can be identified by gross inspection (Figure 10) without a slit-lamp examination. Clinical signs including decreased visual acuity or blurry vision, eye pain with pupillary constriction, and damage to the surrounding ocular structures should prompt careful inspection for the presence of a hyphema.<sup>8,30,32</sup> Hyphemas are typically graded based on the amount of blood within the anterior chamber. Grade I hyphemas fill less than one third of the anterior chamber, grade II fills between one third and one half, grade III fills more than one half, and grade IV is a complete or total hyphema (Figure 11).<sup>30,32</sup>

The management of a traumatic hyphema requires a complete eye examination including intraocular pressure (IOP) measurement and evaluation for a possible ruptured globe.<sup>32</sup> Children with traumatic hyphemas seen in urgent cares should generally be referred to a pediatric ED for further management. The initial emergency management of traumatic hyphema should focus on minimizing secondary hemorrhage and reducing the incidence of secondary glaucoma. The head of the patients' bed should be elevated to 30° to 45° to promote settling of the blood in the anterior chamber away from the visual axis. This improves the diagnosis of secondary hemorrhage and promotes clearance of the hyphema.<sup>30</sup> Eye shielding, which increases patient comfort, should be done as soon as possible to reduce further injury and continued until the hyphema resolves.<sup>8,30,32</sup> Topical analgesics, such as proparacaine, can be effective for acute pain control during examination. If additional pain control is necessary, narcotics can be



**Figure 10** Traumatic hyphema. Note the visible blood in the anterior chamber. Courtesy of Bowling.<sup>56</sup>



**Figure 11.** Total hyphema. Note blood filling the entire anterior chamber. Courtesy of Bowling.<sup>56</sup>

considered. Unlike corneal abrasions where nonsteroid anti-inflammatory agents can be used for pain relief, these therapies should be avoided in hyphemas because of the potential for platelet inhibition and risk of rebleeding. Treatment with antiemetics is recommended to prevent increases in IOP from vomiting.<sup>30-32</sup>

The ED evaluation should include screening for risk factors that place the patient at increased risk for secondary hemorrhage, including sickle cell disease and trait, hemophilia, and von Willebrand disease. Laboratory evaluation including coagulation studies, blood counts, and sickle cell disease testing should be considered in all patients, especially African American patients and those who are unaware of their family histories.<sup>30,32</sup>

Topical cycloplegics are recommended to assist with pain control while also allowing for an optimal examination of the posterior segment. Practitioners can use 1 drop of 1% cyclopentolate or 1 drop of 1% atropine 1 to 3 times daily for up to 5 days.<sup>30,31</sup> It should be noted that the administration of mydriatics has been shown to be a possible risk factor for acute angle-closure glaucoma in patients with acute angle-closure glaucoma of the other eye.<sup>33</sup>

Topical corticosteroids are generally recommended to reduce intraocular inflammation and prevent incidence of secondary hemorrhage but should be reserved for use by an ophthalmologist.<sup>30-32</sup> The utility of systemic corticosteroids to reduce risk of secondary hemorrhage after hyphema is controversial. Historically, 40 mg/day of oral prednisone in adults and 0.6 mg/kg a day in children have been used.<sup>30,34</sup> However, studies supporting the use of systemic corticosteroids were limited by their lack of randomization, and more recent studies have called this practice into question.<sup>30,35,36</sup> In children, prolonged topical steroid can cause rapid increases

in IOP and increases the risk for development of cataracts. Children must be monitored closely for increased IOP, and steroids should be tapered as soon as possible.<sup>8</sup> The potential risks and benefits of steroids should be considered on case-by-case basis in conjunction with ophthalmology consultation.

Systemic antifibrinolytics, such as aminocaproic acid (ACA) and tranexamic acid, have also been used in the treatment of hyphemas. These medications are thought to aid in clot stabilization, allowing more time for the injured vessels to heal and prevent rebleeding.<sup>32</sup> Although earlier studies found that the use of ACA decreased the incidence of secondary hemorrhage,<sup>32,37-39</sup> a recent Cochrane review concluded that the effect of ACA was not significant.<sup>36</sup> The review did find that tranexamic acid reduced the rate of secondary hemorrhage after hyphema; however, this medication is not available in the United States.<sup>31,36</sup> The use of antifibrinolytics needs to be balanced against the known adverse effects of nausea, vomiting, bradycardia, and hypotension. In addition, these medications should be avoided in patients with renal insufficiency and hematuria because they are renally cleared.<sup>32,40</sup>

Hyphemas are associated with increased IOP. Elevated IOP (greater than 22-24 mm Hg) can be treated with topical  $\beta$ -blockers; topical, oral, or intravenous carbonic anhydrase inhibitors (except in sickle hemoglobinopathies); and intravenous mannitol after consultation with an ophthalmologist. Acetazolamide promotes sickling of red blood cells, so methazolamide or humidified transcorneal oxygen is preferred in pediatric patients with sickle cell trait or anemia.<sup>30,32</sup> Humidified transcorneal oxygen is delivered at 1 to 3 L/min and has been shown to rapidly reduce elevated IOP.<sup>41</sup>

Surgical management of hyphema should be considered for hyphemas greater than 50% of the anterior chamber that persist for more than 8 to 10 days, patients with sickle cell trait or anemia, IOP greater than 25 to 35 mm Hg for more than 24 hours, early corneal blood staining, significant visual deterioration, and active bleeding.<sup>8,30,31</sup>

Traumatic hyphemas can be managed in either an outpatient or inpatient setting, depending on the patient age and severity of injury. Outpatient management is preferred in lower-grade injuries in older patients who can be compliant with bed rest, especially in patients at lower risk of rebleeding.<sup>30-32,42</sup> Although strict bed rest has not been found to be beneficial, outpatient management should include elevating the head of the bed and limiting activity.<sup>31,32,43</sup> In the pediatric population, admission to the hospital is recommended if there is penetrating ocular trauma, secondary hemorrhage, suspected child abuse,

hyphema greater than 50%, risk of a noncompliant family, or patients with sickle cell disease or trait.<sup>31,32</sup> Given trends to outpatient management, low-grade hyphemas without other significant injuries may be managed with close follow-up rather than ED evaluation at the discretion of regional resources and the consulting ophthalmologist.<sup>4</sup>

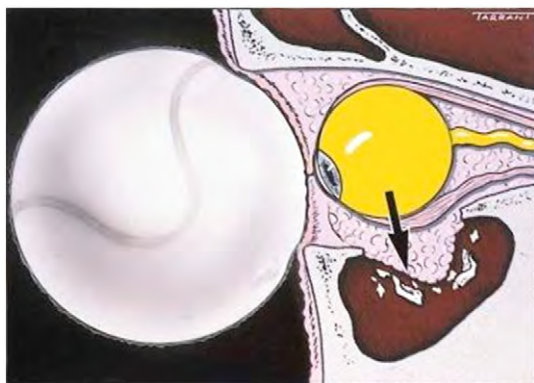
## ORBITAL FRACTURES

Facial trauma is a relatively common complaint in pediatric acute care, accounting for an estimated 11% of pediatric ED visits. Although facial fractures are less common in children relative to adults with similar injuries, pediatric patients are estimated to comprise almost 15% of all maxillofacial fracture patients.<sup>44,45</sup> Orbital fractures are the most common facial fracture in all pediatric age groups, accounting for up to 50% of facial fractures.<sup>46</sup> The most common causes of orbital fractures in young children are motor vehicle accidents, falls, and activities of daily living. Sports- and violence-related facial fractures are more common in older children and adolescents.<sup>44,47</sup>

The clinical examination for orbital injuries in children can be difficult because it may be hard to distinguish a periorbital contusion (“black eye”) from an orbital fracture. Examination of the eyes should include assessment of the pupils, extraocular movements, visual acuity, and surrounding orbital injuries.<sup>47,48</sup> Orbital dystopia (orbits in different planes) and enophthalmos (posterior displacement of the eyeball) are suggestive of an orbital fracture, as are flattening of the nasal complex and telecanthus (increased distance between medial canthi of eyelids).<sup>48,49</sup>

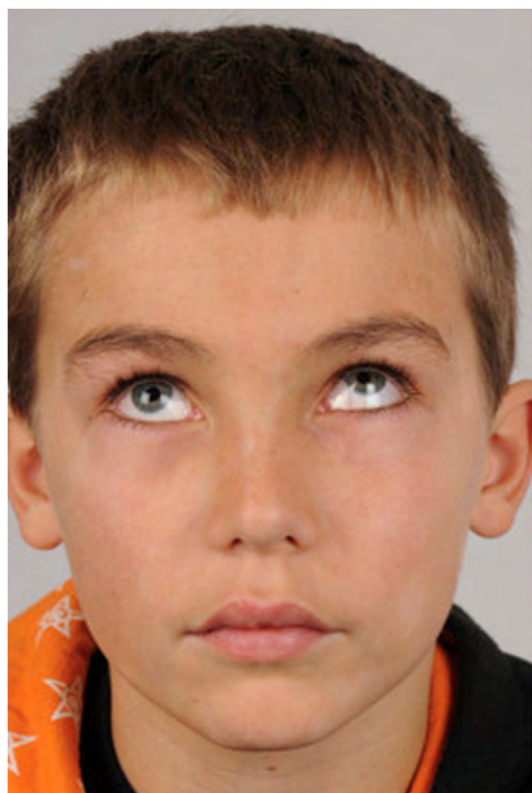Fractures of the floor of the orbit, also known as *blowout fractures*, are the most common orbital fracture in children older than 5 years.<sup>44,48</sup> They typically occur when a medium-sized, hard object such as a baseball strikes the eye at high speed. Typically, the object deforms the eye, causing increased pressure of the intraorbital contents (Figure 12). The periorbital fat is forced through the floor of the orbit, which can lead to enophthalmos and inferior displacement of the eye.<sup>49</sup> When the orbital floor fractures, it often breaks in a linear pattern, causing a “trap door” appearance. This can lead to entrapment of the inferior rectus muscle, clinically appearing as a limited upward gaze (Figure 13). The patient will often complain of pain with eye movement. Practitioners may appreciate restricted eye movement, subcutaneous or conjunctival emphysema, and hypesthesia in the distribution of the infraorbital nerve (ipsilateral cheek and upper lip).<sup>8</sup>





**Figure 12.** Mechanism of an orbital floor fracture. Note the increasing ocular pressure causing displacement of periocular fat pad, leading to lowering of eyeball and subsequent enophthalmos. Courtesy of Bowling.<sup>56</sup>

Fractures of the frontal bone and superior orbital rim are common in children because of the increased ratio of the cranial vault to the facial skeleton. The frontal sinus does not pneumatize until age 6, so these frontal bone fractures are actually cranial fractures and may have increased frequency of intracranial injuries.<sup>46</sup> Fractures of the superior orbital rim may

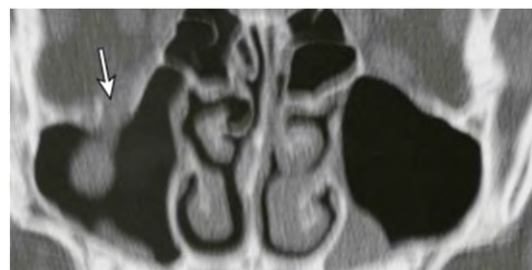


**Figure 13.** Right ocular entrapment in an orbital floor fracture with limited upward gaze. Courtesy of Heggie et al.<sup>61</sup>

be palpable on physical examination, but the diagnosis is often difficult to make without imaging. These fractures require neurosurgical and ophthalmologic involvement. Superior orbital rim fractures rarely require surgical intervention unless there is muscle entrapment. Frontal bone fractures are often repaired to reduce contour deformities. Patients require long-term follow-up because continued brain growth can push apart the fracture site and result in brain herniation requiring cranioplasty.<sup>46</sup>

Naso-orbito-ethmoid fractures are rare in children. They are very difficult to diagnose clinically, often requiring computed tomography (CT). They can result in saddle nose deformity and telecanthus. The management is primarily surgical with open reduction and internal fixation. The need for revision surgery is common especially in growing children.<sup>46</sup>

Plain films are unreliable for the diagnosis of orbital fractures in children, and even when fractures are visualized with plain film, the images are often inadequate to determine extent of injury. Computed tomography is the criterion standard for assessing orbital fractures and guiding the need for reconstruction by evaluating the displacement and volume changes around the orbit (Figure 14).<sup>44,45,47,48</sup> However, because many nondisplaced or minimally displaced pediatric orbital fractures are treated conservatively (nonoperatively), the role for routine CT imaging in the evaluation of orbital fractures is debatable. With increased understanding of the risks of radiation exposure in children in the age of ALARA (as low as reasonably achievable), CT scans should not be reflexively obtained for all pediatric patients with facial trauma.<sup>49</sup> Providers should use discretion and consider deferring CT imaging unless there are signs of severe injury or true signs of muscle entrapment. The ability to detect subtle facial fractures and the potential to change management plans should be weighed against the risk of radiation.<sup>46</sup> When CT imaging is used, low-dose imaging should be used



**Figure 14** CT of right orbital floor blowout fracture. The arrow points to a defect in the orbital floor and "tear drop" signs due to soft tissue prolapse. Courtesy of Bowling.<sup>56</sup>

whenever possible, including discussing specific concerns with the radiologist to minimize excess views and maximize use of reconstructions if possible.<sup>51</sup>

Operative repair is generally recommended for large floor defects ( $>1\text{ cm}^2$ ), for extraocular muscle entrapment, and for patients with significant restriction of extraocular muscle motility.<sup>8,44</sup> Operative repair in children may be less frequent than in adults with similar injuries because orbital growth allows for natural remodeling, especially in young children. In children, the general indications for surgical repair include entrapment of extraocular muscles, early enophthalmos, persistent restrictive strabismus, and diplopia of central gaze.<sup>50</sup>

For conservatively managed orbital fractures, antibiotic administration is indicated if the patient has a history of sinusitis or diabetes or is immunocompromised. In the absence of these risk factors, the use of antibiotics is at the discretion of the treating physician. The patient should be instructed not to blow their nose, and the use of nasal decongestants should be limited to 3 days. Oral steroids should be considered if there is extensive periorbital swelling.<sup>8</sup>

## SUBACUTE PRESENTATIONS OF OPHTHALMOLOGIC INJURY

Some posttraumatic ophthalmologic conditions are less obvious to emergency and urgent care providers upon initial presentation. In these cases, a dilated fundoscopic examination by an ophthalmologist is usually required to confirm the diagnosis. The absence of obvious signs of injury to the anterior chamber and orbit in the setting of delayed ocular symptoms should prompt the provider to consider less obvious diagnoses such as posterior segment injuries which generally require a slit lamp and more thorough examination.

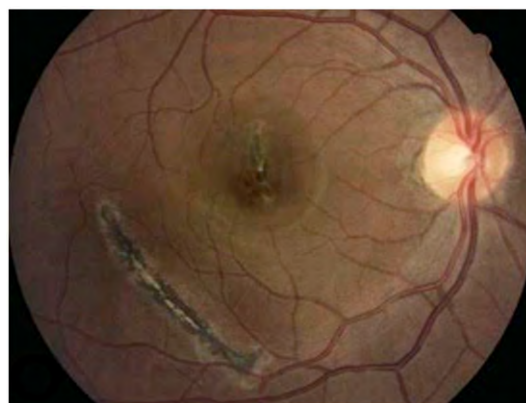
Traumatic iritis and traumatic uveitis (inflammation of the larger uveal tract including the iris, choroid, sclera, and optic nerve) generally occur 24 to 72 hours after blunt trauma to the eye.<sup>4,51</sup> Classically, the patient is a young male complaining of unilateral symptoms of dull, aching eye pain, redness, and light sensitivity a few days after an eye injury.<sup>4,8,52</sup> Diagnosis requires slit lamp microscopy to evaluate for the presence of white blood cells and protein that have leaked into the anterior chamber and aqueous humor due to inflammation of the ocular blood vessels.<sup>4</sup> Management includes discussion with an ophthalmologist for possible dilating drops and/or topical steroids if the patient has significant symptoms.<sup>4,8</sup> Children tend to develop

more complications of uveitis, and there is an increased tendency for corticosteroids to lead to increased IOP and cataracts. Therefore, uveitis in the pediatric patient requires close ophthalmologic follow-up, and steroid drops should only be prescribed under their direction.<sup>4,52</sup>

Vision loss following a trauma may be suggestive of injury to the retrobulbar or posterior segment, especially when there is an absence of obvious findings on anterior and orbit examination. Examples of these subacute injuries include retrobulbar neuritis, choroidal rupture, retinal detachment, and commotion retinae.

Retrobulbar neuritis is a form of optic neuritis in which the optic nerve becomes inflamed and requires urgent intervention. In addition to traumatic causes, retrobulbar neuritis can be caused by infectious, inflammatory, allergic, and exposure etiologies.<sup>5</sup> Vision loss can range from minimal to complete blindness. Patients typically complain of blurry vision, central vision loss, dull-appearing colors, pain with eye movement, or eye tenderness. Subjects may also have decreased pupillary response to light. Emergency consultation with an ophthalmologist is required to aid with the diagnosis and management, including treatment with steroids.<sup>5</sup>

Although choroidal rupture can occur in conjunction with an open globe injury, most are associated with closed globe injuries. They can occur from any type of traumatic injury, including forceps utilization during delivery in neonates.<sup>53,54</sup> Blunt trauma at the site of injury, or from a location opposite to the injury site due to contrecoup forces, may also result in choroidal rupture. Patients present with decreased vision and white or yellow crescent-shaped streaks, usually concentric to the



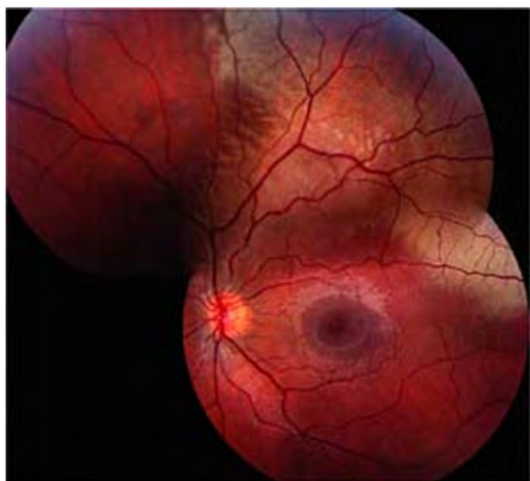**Figure 15.** Choroidal rupture. Note the white crescentic vertical streak of exposed underlying sclera concentric with the optic disc. This only became visible weeks to months later after the absorption of blood. Courtesy of Bowling.<sup>56</sup>

optic disc on fundoscopic examination. Overlying blood concealing the rupture often delays visualization of the injury until days after the trauma has occurred (Figure 15).<sup>8,55</sup>

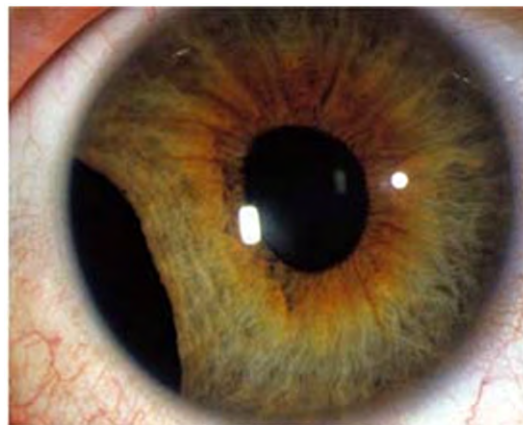Traumatic retinal detachment after blunt trauma can present with symptoms such as flashes of light, floaters, and curtains moving over the field of vision with or without vision loss. Prompt evaluation with a dilated fundus examination is required by an ophthalmologist to confirm the diagnosis, especially because the pediatric population may not be able to verbalize the symptoms above. The location of the detachment and whether or not it involves the macula will guide timing of surgical repair.<sup>8</sup>

Comotio retinae occurs when blunt trauma to the globe causes shock waves that travel posteriorly into the orbit and disrupt the photoreceptors. Patients may complain of decreased vision. On fundoscopic examination, there is a confluent area of retinal whitening from the edema and fragmentation of the photoreceptor outer segments (Figure 16).<sup>8</sup> Visual acuity does not always correlate with the degree of retinal whitening. No treatment is required because the condition clears without therapy.<sup>8</sup>

Iridodialysis, or disinsertion of the iris from the sclera, can occur with blunt trauma or penetrating injuries (Figure 17). Patients are usually asymptomatic unless symptoms of glaucoma develop. Patients should be encouraged to wear sunglasses or contact lenses with an artificial pupil. Surgical correction is reserved for large iridodialysis and/or symptomatic patients. Patient needs to be closely monitored for development of open-angle glaucoma.<sup>8</sup>



**Figure 16.** Comotio retinae. Note the confluent area of retinal whitening with undisturbed blood vessels. Courtesy of Gerstenblith and Rabinowitz.<sup>8</sup>



**Figure 17.** Iridodialysis occurs with blunt trauma or penetrating injury. On visual inspection, the provider can appreciate disinsertion of the iris from the sclera. Courtesy of Gerstenblith and Rabinowitz.<sup>8</sup>

## SUMMARY

The approach to eye injury in children requires a thorough evaluation of visual acuity, ensuring the structural integrity of the eyeball while tailoring the approach to the pediatric patient. A high index of suspicion is necessary for injuries that are vision threatening. Referral to an ED and emergent ophthalmologic consultation are necessary for signs of open globe injury, significant corneal burns, hyphemas, significantly increased IOP, and injuries requiring surgical intervention. Otherwise, most ocular injuries are minor and can be safely managed by arranging close outpatient follow-up with an ophthalmologist when necessary. Understanding the clinical manifestations and examination findings of significant ocular injury is imperative for any frontline provider caring for injured children in an urgent care or ED setting. +

## REFERENCES

1. Nelson LB, Wilson TW, Jeffers JB. Eye injuries in childhood: demography, etiology, and prevention. *Pediatrics* 1989;84: 438-41.
2. Brophy M, Sinclair SA, Hostetler SG, et al. Pediatric eye injury-related hospitalizations in the United States. *Pediatrics* 2006;117:1263-71.
3. McGwin G, Owsley C. Incidence of emergency department-treated eye injury in the United States. *Arch Ophthalmol* 2005;123:662-6.
4. Levin AV. Eye trauma. In: Fleisher GR, Ludwig S, editors. *Textbook of pediatric emergency medicine*, (ed 6). Philadelphia, PA: Lippincott; 2010. p. 1448-58.
5. Naradzay J, Barish RA. Approach to ophthalmologic emergencies. *Med Clin North Am* 2006;90:305-28.



6. Martonyi CL, Maio M. Slip lamp examination and photography. In: Mannis MJ, Holland EJ, editors. *Cornea* (ed 4). Edinburgh, UK: Elsevier; 2017. p. 79-109.
7. Wipperman JL, Dorsch JN. Evaluation and management of corneal abrasions. *Am Fam Phys* 2013;87:114-20.
8. Gerstenblith AT, Rabinowitz MP. *Trauma. The Wills eye manual: office of emergency room diagnosis and treatment of eye disease*. 6th ed, Philadelphia, PA: Lipincott; 2012:13-54.
9. Calder LA, Balasubramanian S, Fergusson D. Topical nonsteroidal anti-inflammatory drugs for corneal abrasions: meta-analysis of randomized trials. *Acad Emerg Med* 2005;12:467-73.
10. Weaver CS, Terrell KM. Update: do ophthalmic nonsteroidal anti-inflammatory drugs reduce the pain associated with simple corneal abrasion without delaying healing? *Ann Emerg Med* 2003;41:134-40.
11. Kim SJ, Flach AJ, Jampol LM. Nonsteroidal anti-inflammatory drugs in ophthalmology. *Surv Ophthalmol* 2010;55:108-33.
12. Carley F, Carley S. Mydriatics in corneal abrasion. *Emerg Med J* 2001;18:273.
13. Turner A, Rabiou M. Patching for corneal abrasion. *Cochrane Database Syst Rev* 2006;19:1-76.
14. Dollery W. Antibiotics and corneal abrasion. *J Accid Emerg Med* 1998;15:352.
15. Kruger RA, Higgins J, Rashford S, et al. Emergency eye injuries. *Aust Fam Phys* 1990;19:934-8.
16. Gangopadhyay N, Daniell M, Weih L, et al. Fluoroquinolone and fortified antibiotics for treating bacterial corneal ulcers. *Ophthalmol* 2000;84:378-84.
17. Parmar P, Salman A, Kalavathy CM, et al. Comparison of topical gatifloxacin 0.3% and ciprofloxacin 0.3% for the treatment of bacterial keratitis. *Ophthalmol* 2006;141:282-6.
18. Chawla B, Agarwal P, Tandon R, et al. In vitro susceptibility of bacterial keratitis isolates to fourth-generation fluoroquinolones. *Ophthalmology* 2010;20:300-5.
19. Hsu HY, Nacke R, Song JC, et al. Community opinions in the management of corneal ulcers and ophthalmic antibiotics: a survey of 4 states. *Eye Contact Lens* 2010;36:195-200.
20. Shah VM, Tandon R, Satpathy G, et al. Randomized clinical study for comparative evaluation of fourth-generation fluoroquinolones with the combination of fortified antibiotics in the treatment of bacterial corneal ulcers. *Cornea* 2010;29:751-7.
21. Gangopadhyay N, Daniell M, Weih L, et al. Fluoroquinolone and fortified antibiotics for treating bacterial corneal ulcers. *Br J Ophthalmol* 2000;84:378-84.
22. Bower KS, Kowalski RP, Gordon YJ. Fluoroquinolones in the treatment of bacterial keratitis. *Br J Ophthalmol* 1996;121:712-5.
23. Spector J, Fernandez WG. Chemical, thermal, and biological ocular exposures. *Emerg Med Clin North Am* 2008;26:125-36.
24. Duffy B. Managing chemical eye injuries. *Managing chemical eye injuries*. *Emerg Nurse* 2008;16:25-9.
25. Pargament JM, Armenia J, Nerad JA. Physical and chemical injuries to eyes and eyelids. *Clin Dermatol* 2015;33:234-7.
26. Thomas A. Household products: non-toxic household products. In: Bateman N, Jefferson R, Thomas S, et al, editors. *Oxford desk reference: toxicology* (ed 1). Oxford, UK: Oxford University Press; 2014. p. 294-5.
27. Marsden J. Ocular burns. *Emerg Nurse* 1999;6:20-4.
28. Chau JP, Lee DT, Lo SH. A systematic review of methods of eye irrigation for adults and children with ocular chemical burns. *Worldviews Evid Based Nurs* 2012;9:129-38.
29. Parul S, Manoj T, Yogesh K, et al. Ocular chemical injuries and their management. *Ophthalmol* 2013;6:83-6.
30. Brandt MT, Haug RH. Traumatic hyphema: a comprehensive review. *J Oral Maxillofac Surg* 2001;59:1462-70.
31. Walton W, Von Hagen S, Grigorian R, et al. Management of traumatic hyphema. *Surv Ophthalmol* 2002;47:297-334.
32. Sankar PS, Chen TC, Grosskreutz CL, et al. Traumatic hyphema. *Int Ophthalmol Clin* 2002;42:57-68.
33. Edwards RS. Behaviour of the fellow eye in acute angle-closure glaucoma. *Ophthalmology* 1982;66:576-9.
34. Yasuna E. Management of traumatic hyphema. *Arch Ophthalmol* 1974;91:190-1.
35. Spoor TC, Hammer M, Belloso H. Traumatic hyphema. Failure of steroids to alter its course: a double-blind prospective study. *Arch Ophthalmol* 1980;98:116-9.
36. Gharaibeh A, Savage HI, Scherer RW, et al. Medical interventions for traumatic hyphema. *Cochrane Database Syst Rev* 2013;12:1-151.
37. Crouch Jr ER, Frenkel M. Aminocaproic acid in the treatment of traumatic hyphema. *Ophthalmology* 1976;81:355-60.
38. McGetrick JJ, Jampol LM, Goldberg MF, et al. Aminocaproic acid decreases secondary hemorrhage after traumatic hyphema. *Arch Ophthalmol* 1983;101:1031-3.
39. Kutner B, Fourman S, Brein K, et al. Aminocaproic acid reduces the risk of secondary hemorrhage in patients with traumatic hyphema. *Arch Ophthalmol* 1987;105:206-8.
40. Berríos RR, Dreyer EB. Traumatic hyphema. *Int Ophthalmol Clin* 1995;35:93-103.
41. Benner JD. Transcorneal oxygen therapy for glaucoma associated with sickle cell hyphema. *Ophthalmology* 2000;130:514-5.
42. Shiuey Y, Lucarelli MJ. Traumatic hyphema: outcomes of outpatient management. *Ophthalmology* 1998;105:851-5.
43. Wright KW, Sunalp M, Urrea P. Bed rest versus activity ad lib in the treatment of small hyphemas. *Ann Ophthalmol* 1988;20:143-5.
44. Broyles JM, Jones D, Bellamy J, et al. Pediatric orbital floor fractures: outcome analysis of 72 children with orbital floor fractures. *Plast Reconstr Surg* 2015;136:822-8.
45. Boyette JR. Facial fractures in children. *Otolaryngol Clin North Am* 2014;47:747-61.
46. Grunwaldt L, Smith DM, Zuckerbraun NS, et al. Pediatric facial fractures: demographics, injury patterns, and associated injuries in 772 consecutive patients. *Plast Reconstr Surg* 2011;128:1263-71.
47. Cobb AR, Jeelani NO, Ayliffe PR. Orbital fractures in children. *Oral Maxillofac Surg* 2013;51:41-6.
48. Neuman MI. Facial trauma. In: Fleisher GR, Ludwig S, editors. *Textbook of pediatric emergency medicine*, ed. 6. Philadelphia, PA: Lippincott, 2010. p. 1307-34.
49. Murchinson AP, Matthews AE, Bilyk JR. Specific issues in pediatric periocular trauma. In: Black EH, Nesi FA, Calvano C, et al, editors. *Smith and Nesi's ophthalmic plastic and reconstructive surgery*, ed 3. New York, NY: Springer; 2012. p. 1227-47.
50. Coon D, Kosztowski M, Mahoney NR, et al. Principles for management of orbital fractures in the pediatric population: a cohort study of 150 patients. *Plast Reconstr Surg* 2016;137:1234-40.
51. Engelhard SB, Patrie J, Prenshaw J, et al. Traumatic uveitis in the mid-Atlantic United States. *Clin Ophthalmol* 2015;9:1869-74.
52. Cunningham ET. Uveitis in children. *Ocul Immunol Inflamm* 2000;8:251-61.

53. Patel MM, Chee YE, Elliott D. Choroidal rupture: a review. *Int Ophthalmol Clin* 2013;53:69-78.
54. Estafanous MF, Seeley M, Traboulsi EI. Choroidal rupture associated with forceps delivery. *Ophthalmology* 2000;18: 84-8.
55. Navon SE. Management of the ruptured globe. *Int Ophthalmol Clin* 1995;35:71-91.
56. Bowling B. Trauma. *Kanski's clinical ophthalmology: a systematic approach*. 8th ed. China: Saunders, 2016. p. 861-85.
57. Hoffman RS. Corneal abrasion, in Ferri FF. *Ferri's clinical advisor*. Philadelphia, PA: Elsevier; 2017, p.323.
58. Ahmed F, House RJ, Feldman BH. Corneal abrasions and corneal foreign bodies. *Prim Care* 2015;42:363-75.
59. Pfister RR, Pfister DA. Chemical injuries of the eye. In: Brightbill FS, editor. *Corneal surgery: theory, technique and tissue*. 4th ed. St. Louis, MO: Mosby, 2009. p. 605-15.
60. Rao NK, Goldstein MH. Acid and alkali burns. In: Myron Y, Duker JS, editors. *Ophthalmology*, 4th ed. London: Elsevier, 2013. p. 296-8.
61. Heggie AA, Vujcich NJ, Shand JM, et al. Isolated orbital floor fractures in the paediatric patient: case series and review of management. *Oral Maxillofac Surg* 2015;44:1250-4.