

Diagnostic Accuracy of the HINTS Exam in an Emergency Department: A Retrospective Chart Review

Cait Dmitriew, PhD¹ , Aaron Regis, BSc¹, Oluwadamilola Bodunde, BSc¹, Rory Lepage, BSc¹, Zachary Turgeon¹, Sarah McIsaac, MBBCh, MEd², and Robert Ohle, MBBCh, MA, MSc³ 

ABSTRACT

Introduction: The HINTS exam is a series of bedside ocular motor tests designed to distinguish between central and peripheral causes of dizziness in patients with continuous dizziness, nystagmus, and gait unsteadiness. Previous studies, where the HINTS exam was performed by trained specialists, have shown excellent diagnostic accuracy. Our objective was to assess the diagnostic accuracy of the HINTS exam as performed by emergency physicians on patients presenting to the emergency department (ED) with a primary complaint of vertigo or dizziness.

Methods: A retrospective cohort study was performed using data from patients who presented to a tertiary care ED between September 2014 and March 2018 with a primary complaint of vertigo or dizziness. Patient characteristics of those who received the HINTS exam were assessed along with sensitivity and specificity of the test to rule out a central cause of stroke.

Results: A total of 2,309 patients met criteria for inclusion in the study. Physician uptake of the HINTS exam was high, with 450 (19.5%) dizzy patients receiving all or part of the HINTS. A large majority of patients (96.9%) did not meet criteria for receiving the test as described in validation studies; most often this was because patients lacked documentation of nystagmus or described their symptoms as intermittent. In addition, many patients received both HINTS and Dix-Hallpike exams, which are intended for use in mutually exclusive patient populations. In no case was dizziness due to a central cause identified using the HINTS exam.

Conclusions: Our results suggest that despite widespread use of the HINTS exam in our ED, its diagnostic value in that setting was limited. The test was frequently used in patients who did not meet criteria to receive the HINTS exam (i.e., continuous vertigo, nystagmus, and unsteady gait). Additional training of emergency physicians may be required to improve test sensitivity and specificity.

Dizziness is a common presentation in emergency departments (EDs), accounting for 1% to 3% of all visits.^{1,2} Diagnoses can range from benign, peripheral causes such as benign paroxysmal positional vertigo (BPPV) and vestibular neuritis to life-threatening central nervous system (CNS) pathologies including cerebellar and brainstem strokes. Up to one-third of these strokes are missed at the initial assessment.^{3,4} Acute vertigo caused by posterior circulation strokes is often accompanied by other focal neurologic deficits—

From the ¹Department of Undergraduate Medicine, Northern Ontario School of Medicine, Sudbury, Ontario; the ²Department of Critical Care, Department of Anesthesia, Northern Ontario School of Medicine, Sudbury, Ontario, Canada; and the ³Department of Emergency Medicine, Health Science North Research Institute, Northern Ontario School of Medicine, Sudbury, Ontario, Canada.

Received September 24, 2020; revision received November 2, 2020; accepted November 4, 2020.

The authors have no relevant financial information or potential conflicts to disclose.

Author contributions: CD was responsible for analysis and manuscript preparation; ZT, AR, RL, and OB were responsible for data extraction; SM contributed to manuscript preparation; RO was responsible for study design, oversight, and manuscript editing; and RO acts as guarantor for accuracy and integrity of the manuscript.

Supervising Editor: J. Stephen Huff, MD.

Address for correspondence and reprints: Robert Ohle; e-mail: Robert.ohle@gmail.com.

ACADEMIC EMERGENCY MEDICINE 2021;28:387–393.

but not always, making it difficult to distinguish from peripheral causes of continuous dizziness such as vestibular neuritis.^{3,5}

The HINTS exam (Head Impulse, Nystagmus, Test of Skew) is a series of three bedside ocular motor tests that can be used to differentiate central from peripheral causes of dizziness in patients with symptoms consistent with acute vestibular syndrome (AVS). It has been proposed as a useful tool in EDs to improve diagnostic accuracy for patients with isolated dizziness.⁶ However, most validation studies to date have studied the diagnostic accuracy of HINTS as performed by neurologists or otolaryngologists in high stroke prevalence populations.⁷ What we do not know is whether the HINTS exam has similarly high sensitivity when performed by emergency physicians in the ED setting, where the prevalence of central causes of dizziness is much lower and where training in the use of the examination may be less consistent or intensive.

METHODS

Study Objective

Our objective was to assess the frequency of use of the HINTS exam, the characteristics of patients in whom it is applied, and the sensitivity and specificity of the test to detect a central cause for dizziness as it is used by emergency room physicians.

Study Setting and Criteria

A retrospective medical records review was performed for all patients presenting to a tertiary care ED in Ontario, Canada, between September 2014 and March 2018 who received a triage diagnosis of dizziness, vertigo, light-headedness, and/or unsteadiness. Patients were excluded from the study if they left without being seen, had dizziness > 14 days, recent trauma, a Glasgow Coma Scale score of less than 15, or hypotension (sBP < 90) or reported syncope/loss of consciousness (Figure 1). Physicians received no special training on the HINTS exam prior to the study period.

Data Acquisition

Data were extracted by five trained reviewers according to guidelines put forward by Jansen et al.⁸ Parameters were extracted and compiled according to the criteria outlined in the Data Supplement S1 (available as supporting information in the online version of this paper, which is available at <http://onlinelibrary.wiley.com/doi/10.1111/acem.14171/full>).

These included features of the presenting illness, associated symptoms, physical exam findings, and imaging orders. The independent variables that were collected were generated by systematic review of the literature and expert opinion. Data were extracted from multiple sources including ED records, consultant notes, and the Institute of Clinical Evaluation Sciences (ICES) database. A subset of 20 charts was coded by all investigators to establish inter-rater reliability, and kappa was calculated with the data extraction form considered as a single variable, such that if any variable on the form varied between reviewers it was counted as a disagreement.

Outcomes of Interest

The primary outcome measure was the diagnostic accuracy of the HINTS exam, that is, the number of patients who had a central HINTS exam and who were diagnosed with a CNS cause for their dizziness. CNS causes of dizziness included stroke, transient ischemic attack (TIA), brain tumor, or multiple sclerosis (MS). Diagnoses were confirmed by computed tomography (CT), magnetic resonance imaging (MRI), neurology consult, or diagnostic codes within ICES.

Our secondary outcomes were: 1) the number of dizzy patients that had symptoms consistent with AVS and who appropriately received a HINTS exam; 2) the proportion of HINTS exams that were performed on dizzy patients who were not appropriate candidates to receive the HINTS exam; and 3) the number of patients presenting with dizziness who received both the HINTS exam and the Dix-Hallpike test for BPPV, which tests intended for use in nonoverlapping patient populations.

Criteria to Receive HINTS Exam

The HINTS exam is only applicable in patients presenting with AVS, which has been defined in validation studies of the HINTS exam as acute-onset, continuous vertigo associated with gait unsteadiness, nausea and/or vomiting, and spontaneous or gaze-evoked nystagmus.^{5,9} It is not applicable in patients with episodic, positionally evoked vertigo, as is typical of BPPV, a common cause of vertigo.¹⁰ Specific inclusion and exclusion criteria vary somewhat among validation studies of the HINTS exam; we follow those used by Kerber et al.¹¹ These are continuous dizziness ongoing at the time of presentation to the ED, nystagmus, and gait unsteadiness. Given the constraints of

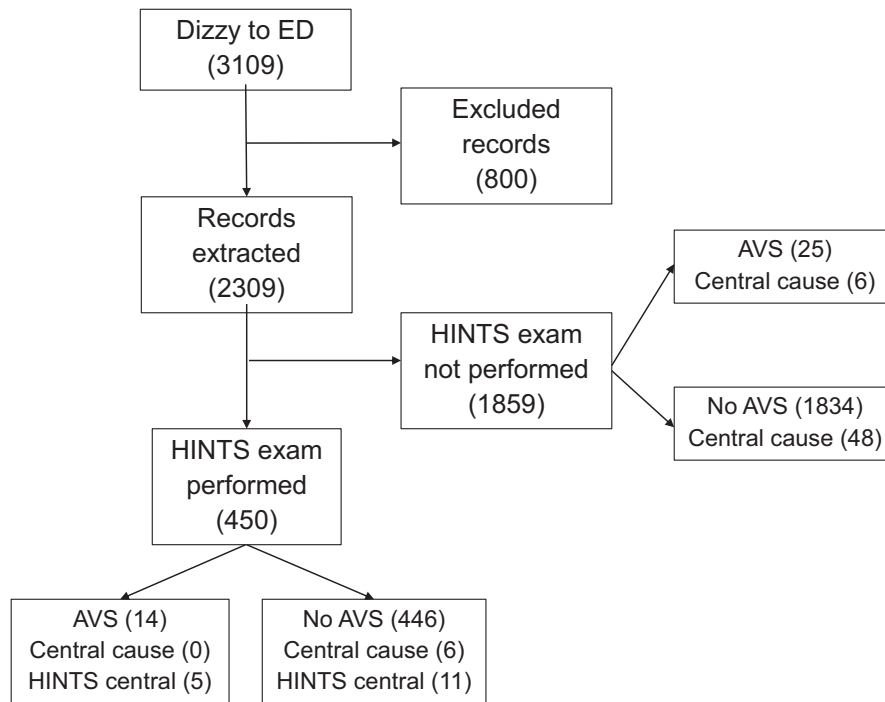


Figure 1. Flow diagram of study inclusion and HINTS exam testing. Exclusions: patients were excluded from the study if they left without being seen or had dizziness > 14 days, recent trauma, a Glasgow Coma Scale score of less than 15, hypotension (sBP < 90), or reported syncope/loss of consciousness. Central cause = number of patients diagnosed with a central cause for dizziness. HINTS central = number of patients with HINTS exam findings consistent with a central cause of dizziness (see main text). AVS = acute vestibular syndrome.

the retrospective chart review, symptoms of AVS were approximated from patient records as follows:

1. Nystagmus and unsteady gait: documentation of both signs was required to meet AVS criteria. If either sign was not explicitly documented, the patient was considered to be inappropriate candidate for the HINTS exam.
2. Symptom timing: patients were considered to be appropriate candidates for the HINTS exam unless documented characteristics of dizziness were clearly inconsistent with AVS—that is, symptoms had resolved by the time they were seen by the emergency physician or symptoms were described as “intermittent.” When no documentation was provided regarding symptom timing, it was assumed that the dizziness was continuous and ongoing at the time of examination. The analysis was repeated using only those patients for whom dizziness was documented explicitly as being continuous and ongoing, to assess for differences in test sensitivity or specificity resulting from the use of stricter criteria.
3. Focal neurologic deficits: Patients with documented focal neurologic deficits consistent with a central cause of vertigo (diplopia, dysarthria,

dysphagia, dysmetria or truncal ataxia, or sensory or physical deficits noted on physical exam) were retained; HINTS validation studies are mixed in this regard, although the presence of obvious neurologic deficits may obviate the need for a HINTS exam.^{4,11}

Interpreting the Results of the HINTS Exam

The HINTS exam was considered to be central (positive) when one or more components of the exam were consistent with a central cause for dizziness:⁴

- Head impulse test: corrective saccade absent;
- Nystagmus: direction-changing;
- Test of skew: vertical deviation followed by correction on cover–uncover test.

HINTS was considered to be peripheral (negative) when all three of the exam components were consistent with a peripheral cause: that is, a corrective saccade was noted on head impulse test, nystagmus was unidirectional, and vertical skew was absent.

Data Analysis

Data analysis was primarily descriptive. Sensitivity and specificity were calculated using the Clopper-Pearson exact method in R (4.0.0).

Institutional Review Board Approval

The Health Sciences North Research Ethics board approved this research.

RESULTS

A total of 3,109 patients presented to the ED with a complaint of dizziness, vertigo, unsteadiness, and/or lightheadedness between September 2014 and March 2018, of whom 2309 met inclusion criteria (Figure 1). For data extraction, the kappa score for inter-rater reliability was 0.91 (95% confidence interval [CI] = 0.87 to 0.93).

Of the 2,309 total patients presenting to the ED with dizziness, 39 (1.7%) had documentation of signs and symptoms consistent with AVS (ongoing, continuous dizziness accompanied by both nystagmus and unsteady gait) and so were candidates to receive a HINTS exam. Of these, 14 (36%) received one. Six (15.4%) AVS patients were ultimately diagnosed with stroke or other central cause for dizziness, although none of these patients were among those who received the HINTS exam (Figure 1).

A total of 450 (19.5%) included patients received a HINTS exam in the ED; the remainder of the results section focuses solely on these patients. The majority of patients assessed with the HINTS exam had documentation of all three components (78%). The most common component was the assessment for direction changing nystagmus (96%) followed by test of skew (94%) and the head impulse test (86%). A total of 37 patients had one or more additional neurologic deficits, and the most common ED discharge diagnoses were dizziness, vertigo, or light-headedness not otherwise specified (Table 1).

Use of the HINTS Exam

The HINTS exam was used on patients with symptoms consistent with AVS in 14 of 450 HINTS exams (3.1% of the time). The remaining 436 patients had one or more characteristics inconsistent with AVS as defined in prior validation studies. Most often, they lacked documentation of nystagmus or ataxia, or their symptoms were documented as being intermittent (Table 2).

Notably, of all patients receiving a HINTS exam, 220 (49%) were documented as also having received a Dix-Hallpike test, which is used to diagnose BPPV in patients with brief (<2 minutes), intermittent episodes of vertigo triggered by a change in head position relative to gravity.¹²

Table 1
Characteristics of Patients Assessed With HINTS Exam

	<i>n</i> (%)
Total	450
Age (years), mean (\pm SD)	57.4 (\pm 18.7)
Male	198 (44)
Description of presenting symptom(s)	
Vertigo	277 (62.6)
Dizzy	401 (89.1)
Lightheaded	159 (35.3)
Unsteady	91 (20.2)
Associated signs	
Nystagmus	78 (17.3)
Unsteady gait	92 (20.4)
Motor deficit	4 (0.9)
Sensory deficit	3 (0.7)
Dysmetria	8 (1.8)
Dysphagia	1 (0.0)
Dysarthria	7 (1.6)
Diplopia	19 (4.2)
Truncal ataxia	1 (0.0)
ED discharge diagnosis	
Dizzy, lightheaded, or vertigo not otherwise specified	132 (29.3)
Peripheral vertigo not otherwise specified	141 (31.3)
Benign paroxysmal positional vertigo	74 (16.4)
Meniere's disease	3 (0.1)
Vestibular neuritis or labyrinthitis	8 (1.8)
Stroke	4 (0.9)
Transient ischemic attack	1 (0.0)
Multiple sclerosis	1 (0.0)
Other	86 (19.1)
Imaging ordered	
MRI	26 (5.8)
CT	148 (32.9)
CTA	16 (3.6)

HINTS = Head Impulse, Nystagmus, Test of Skew; MRI = magnetic resonance imaging.

Table 2
Application of HINTS Exam in Patients Presenting With Dizziness

	Not Appropriate for HINTS, <i>n</i> (%)	Appropriate for HINTS, <i>n</i> (%)
Total	436 (96.9)	14 (3.1)
Characteristics of vertigo/dizziness*		
Dizziness resolved	87	
Intermittent dizziness	200	
Associated signs		
No documented unsteady gait	358	
No documented nystagmus	372	

*If duration of dizziness was not documented, it was assumed to be continuous.

Sensitivity and Specificity of the HINTS Exam

Of all patients assessed with the HINTS, 16 patients (3.6%) were found to have one or more components of the exam consistent with a central cause of dizziness (Figure 1). However, none of these patients were ultimately diagnosed with one (specificity 0.95 [95% CI = 0.94 to 0.98]). Among those patients deemed to be appropriate candidates for the HINTS, five patients had a false-positive, HINTS-central result (specificity 0.64 [95% CI = 0.35 to 0.87]).

None of the patients who were assessed with HINTS and who were ultimately diagnosed with a central cause of dizziness had a HINTS central result. Six patients (1.3%) were found to have a central cause for their dizziness (stroke [4], TIA [1], and MS [1]), yet none had documentation of signs and symptoms consistent with AVS. Four of these patients had intermittent dizziness, and three had no nystagmus documented. Therefore, the sensitivity of the HINTS exam could not be determined for this population.

A total of 175 patients had no documentation regarding the duration of dizziness. When the data were analyzed using only those patients for whom dizziness was explicitly documented as continuous, only six of 450 patients met criteria for having AVS. However, specificity was not improved by using these strict criteria (specificity = 0.67, 95% CI = 0.22 to 0.97).

DISCUSSION

Our retrospective chart review revealed that uptake of the HINTS exam by emergency physicians at our facility is quite high, with 19.5% of dizzy patients having been assessed with the HINTS exam. Despite the relatively high test utilization, the majority of patients with AVS did not receive one. Instead, few patients who were assessed with the HINTS appeared to be appropriate candidates for this exam. The HINTS exam is designed to distinguish between central and peripheral causes for AVS, which is defined as acute-onset, continuous vertigo or dizziness accompanied by nystagmus and gait unsteadiness and has been validated only for patients meeting these criteria.^{4,9,11} In our study, only 3.1% of HINTS patients had documentation consistent with AVS, suggesting that the test is frequently performed on patients who are not appropriate candidates to receive it.

Validation studies have demonstrated test sensitivity and specificity to identify posterior circulation stroke in

AVS patients approaching 100%.⁴ The exam may even outperform MRI when conducted within 48 hours of symptom onset. An accurate bedside exam may therefore reduce unnecessary imaging by ruling out a central cause of dizziness in this patient population, leading to calls for increased use of the HINTS exam by ED physicians.^{9,17,18} Indeed, test utilization appears to be relatively high and increasing; a previous study at a different Ontario tertiary care center showed that 7.1% of dizzy patients received the HINTS exam between 2010 and 2014 and that test use increased over the study period.¹⁹

The results of our study suggest that while the exam is frequently used in the ED, it is not always used appropriately, and there appears to be a need for additional education regarding the characteristics of patients in whom it is validated for use. Test sensitivity and specificity appear to be dependent on the level of experience and training of clinicians, and less experienced clinicians are more likely to miss subtle positive HITs.^{11,20,21} HINTS validation studies have to date relied on ocular motor examinations conducted by neurologists or neuroophthalmologists.⁷ To our knowledge, no previous study has examined the sensitivity and specificity of HINTS as conducted by ED physicians, although Vanni et al.²² describe high sensitivity and specificity among ED physicians who received additional training to perform a group of similar bedside ocular motor tests. As no standardized HINTS training was provided prior to the study period, the type and duration of training in the HINTS exam at our facility is likely to vary substantially between clinicians depending on many factors such as level of experience and educational background.

Using the HINTS exam on patients who do not meet criteria for AVS may lead to harms. In particular, the interpretation of the HIT depends on whether AVS is present or absent. In patients who meet AVS criteria, the absence of a corrective saccade is worrisome and raises suspicion for a posterior circulation stroke. Conversely, a corrective saccade is reassuring in these patients because it is diagnostic of vestibular neuritis, a common benign cause of AVS. In patients who do not meet AVS criteria, the absence of a corrective saccade is the normal, expected result and thus has no diagnostic utility to rule in or rule out stroke. When conducted in inappropriate patients, this normal pattern could be erroneously interpreted as being a sinister finding and trigger additional, unnecessary investigation. It should be further noted that positive findings on the other two components of the HINTS exam (nystagmus and test of skew) are worrisome regardless of whether the patient

meets AVS criteria or not, as are other obvious ocular motor abnormalities such as spontaneous vertical nystagmus or gaze palsy.⁴

Interestingly, we found relatively few false-positive tests despite the many hundreds of patients without AVS who received the HINTS exam. There are two possible explanations. First, some patients may in fact have been appropriate candidates despite documentation suggesting otherwise: for example, nystagmus or gait unsteadiness may have been present but were not documented. Alternatively, the lack of HINTS exams documented as “central” may reflect the challenge of clearly documenting the results.¹³ For example, if a patient was found to have no corrective saccade on HIT, but was ultimately diagnosed as having BPPV, the HIT may have been documented as being “peripheral,” although in the context of the HINTS exam it would have correctly been documented as “central.”

Notably, many patients received both the HINTS and Dix-Hallpike tests, which are designed for use in mutually exclusive patient populations: those with continuous, spontaneous vertigo and those with brief episodes of vertigo triggered by changes in head position relative to gravity, respectively. This finding, in conjunction with the finding that the majority of HINTS exams appear to be conducted in patients who do not meet criteria for AVS, suggests that physicians are uncertain which patients are appropriate candidates for HINTS. It also underscores the challenge of obtaining accurate descriptions of the timing and triggers of vertigo, because many patients with BPPV may endorse continuous dizziness because they feel unwell between discrete episodes of vertigo. This has been recognized as an important pitfall in determining which patients are candidates for each exam.¹⁴

The prevalence of AVS among patients presenting to the ED with dizziness is unknown, although it has been estimated as being between 10% and 20%.¹⁵ Thus, it is likely that our chart review did not identify all AVS patients. One factor contributing to the low number of AVS patients identified in our study was the lack of documented or observed nystagmus, which was the feature of AVS that was most frequently missing in the documentation of patients who received a HINTS exam. One reason may be that physicians observed nystagmus but simply did not document it consistently. Alternatively, nonspecialists, who may have less experience or be less likely to have access to devices such as Frenzel goggles, may be more likely to miss subtle nystagmus on exam. For this reason, it has been suggested that patients be

instructed to look through a sheet of blank white paper while assessing for nystagmus to eliminate fixation.¹⁴ The true absence of nystagmus in patients with unsteady gait and continuous dizziness ongoing at the time of assessment is nonreassuring, because these patients are unlikely to have vestibular neuritis but do have an increased risk of being diagnosed with a stroke.¹⁶

LIMITATIONS

The limitations of our study include the fact that it is a single-center retrospective chart review. Results may not be generalizable to other centers, which may have different training or documentation practices around the HINTS exam, and we did not control for individual physicians or their level of education or experience. However, given the relatively recent development of the HINTS exam, it is likely that the issues we identified are also applicable to other EDs whose physicians have not received standardized training in performing and interpreting the HINTS exam.

The retrospective chart review approach depends on completeness and accuracy of physician documentation. We assumed that characteristics of AVS that were not documented (such as nystagmus and unsteady gait) were not present, which is likely to have artificially reduced the proportion of tests considered to be appropriate. However, the lack of documentation of nystagmus and ataxia does suggest that some users may not appreciate that these signs are required. Conversely, our decision to assume that patients without explicit documentation of symptom duration had continuous vertigo may have caused us to include too many patients, reducing specificity.

Finally, the number of patients with central cause of vertigo who received a HINTS exam was low ($n = 6$), and we found that none of these patients met criteria for AVS. Therefore, we were unable to accurately assess test sensitivity in this population. Future prospective studies should directly compare the diagnostic accuracy of the HINTS exam as conducted by emergency physicians to that of experts and imaging. Further study is needed to understand the specific barriers to appropriate use of the HINTS exam by ED physicians and to identify the most effective practical interventions. Reliability of HINTS scoring data may be improved by facilitating accurate and complete documentation of the exam. This might be accomplished by embedding inclusion criteria and a documentation template for the HINTS exam in the electronic

medical record, thereby removing ambiguity in documentation of the HIT component.

CONCLUSION

The HINTS exam has been proposed as a useful clinical tool to help rule out dangerous central nervous system conditions in patients presenting with dizziness. However, we found that it was frequently used in patients who were not appropriate candidates for the exam based on their reported symptoms and accompanying signs. Our results suggest that the test is of limited utility as currently used by ED physicians and that additional training in how to identify appropriate candidates and interpret the results of the ocular motor exam may improve its diagnostic accuracy.

REFERENCES

- Kerber KA, Meurer WJ, West BT, Mark FA. Dizziness presentations in US emergency departments, 1995–2004. *Acad Emerg Med* 2008;15:744–50.
- Atzema CL, Grewal K, Lu H, Kapral MK, Kulkarni G, Austin PC. Outcomes among patients discharged from the emergency department with a diagnosis of peripheral vertigo. *Ann Neurol* 2016;79:32–41.
- Kerber KA, Brown DL, Lisabeth LD, Smith MA, Morgenstern LB. Stroke among patients with dizziness, vertigo, and imbalance in the emergency department: a population-based study. *Stroke* 2006;37:2484–8.
- Kattah JC, Talkad AV, Wang DZ, Hsieh YH, Newman-Toker DE. HINTS to diagnose stroke in the acute vestibular syndrome: three-step bedside oculomotor examination more sensitive than early MRI diffusion-weighted imaging. *Stroke* 2009;40:3504–10.
- Hotson JR, Baloh RW. Differentiating between peripheral and central causes of vertigo. *N Engl J Med* 1998;339:680–5.
- Newman-Toker DE, Edlow JA. TiTrATE: a novel, evidence-based approach to diagnosing acute dizziness and vertigo. *Neurol Clin* 2015;33:577–99.
- Ohle R, Montpellier R, Marchadier V, et al. Can emergency physicians accurately rule out a central cause of vertigo using the HINTS exam? A systematic review and meta-analysis. *Acad Emerg Med* 2020;27:887–96.
- Jansen AC, van Aalst-Cohen ES, Hutten BA, Büller HR, Kastelein JJ, Prins MH. Guidelines were developed for data collection from medical records for use in retrospective analyses. *J Clin Epidemiol* 2005;58:269–74.
- Newman-Toker DE, Kerber KA, Hsieh YH, et al. HINTS outperforms ABCD2 to screen for stroke in acute continuous vertigo and dizziness. *Acad Emerg Med* 2013;20:986–96.
- Parker IG, Hartel G, Paratz J, Choy NL, Rahmann A. A systematic review of the reported proportions of diagnoses for dizziness and vertigo. *Otol Neurotol* 2019;40:6–15.
- Kerber KA, Meurer WJ, Brown DL, et al. Stroke risk stratification in acute dizziness presentations: a prospective imaging-based study. *Neurology* 2015;85:1869–78.
- Bhattacharyya N, Gubbels SP, Schwartz SR, et al. Clinical practice guideline: benign paroxysmal positional vertigo (update). *Otolaryngol Head Neck Surg* 2017;156:S1–47.
- Thomas DB, Newman-Toker DE. Avoiding “HINTS Positive/Negative” to minimize diagnostic confusion in acute vertigo and dizziness. *J Acute Care Physical Therapy* 2016;7:129–31.
- Edlow JA, Gurley KL, Newman-Toker DE. A new diagnostic approach to the adult patient with acute dizziness. *J Emerg Med* 2018;54:469–83.
- Tarnutzer AA, Berkowitz AL, Robinson KA, Hsieh YH, Newman-Toker DE. Does my dizzy patient have a stroke? A systematic review of bedside diagnosis in acute vestibular syndrome. *CMAJ* 2011;183:E571–92.
- Machner B, Choi JH, Trillenber P, Heide W, Helmchen C. Risk of acute brain lesions in dizzy patients presenting to the emergency room: who needs imaging and who does not? *J Neurol* 2020 [Online ahead of print].
- Johns P, Quinn J. Clinical diagnosis of benign paroxysmal positional vertigo and vestibular neuritis. *CMAJ* 2020;192:E182–6.
- Saber Tehrani AS, Kattah JC, Kerber KA, et al. Diagnosing stroke in acute dizziness and vertigo: pitfalls and pearls. *Stroke* 2018;49:788–95.
- Quimby AE, Kwok ES, Lelli D, Johns P, Tse D. Usage of the HINTS exam and neuroimaging in the assessment of peripheral vertigo in the emergency department. *J Otolaryngol Head Neck Surg* 2018;47:54.
- Newman-Toker DE. Comment: diagnosing stroke in acute dizziness—do the “eyes” still have it? *Neurology* 2015;85:1877.
- Jorns-Haderli M, Straumann D, Palla A. Accuracy of the bedside head impulse test in detecting vestibular hypofunction. *J Neurol Neurosurg Psychiatry* 2007;78:1113–8.
- Vanni S, Nazerian P, Casati C, et al. Can emergency physicians accurately and reliably assess acute vertigo in the emergency department? *Emerg Med Australas* 2015;27:126–31.

Supporting Information

The following supporting information is available in the online version of this paper available at <http://onlinelibrary.wiley.com/doi/10.1111/acem.14171/full>

Data Supplement S1. Definitions used in retrospective chart review data collection.