

## CLINICAL PRACTICE

Caren G. Solomon, M.D., M.P.H., *Editor*

## Epistaxis

Hadi Seikaly, M.D.

*This Journal feature begins with a case vignette highlighting a common clinical problem. Evidence supporting various strategies is then presented, followed by a review of formal guidelines, when they exist. The article ends with the author's clinical recommendations.*

**A 65-year-old man presents to the emergency department with a 2-hour history of epistaxis. He has hypertension and atrial fibrillation and takes amlodipine, hydrochlorothiazide, and warfarin. On examination, he is comfortable but bleeding continuously from the left nostril. His blood pressure is 150/80 mm Hg, and his heart rate is 80 beats per minute. How would you treat this patient?**

## THE CLINICAL PROBLEM

From the Division of Otolaryngology–Head and Neck Surgery, University of Alberta, Edmonton, Canada. Address reprint requests to Dr. Seikaly at the Division of Otolaryngology–Head and Neck Surgery, University of Alberta, Walter C. MacKenzie Health Sciences Centre, Rm. 1E4.33, Clinical Sciences Bldg., 8440 112 St. NW, Edmonton, AB, T6G 2B7, Canada, or at [hseikaly@ualberta.ca](mailto:hseikaly@ualberta.ca).

N Engl J Med 2021;384:944–51.

DOI: 10.1056/NEJMcp2019344

Copyright © 2021 Massachusetts Medical Society.



**An audio version  
of this article  
is available at  
[NEJM.org](https://www.nejm.org)**

**E**PISTAXIS IS A FREQUENTLY ENCOUNTERED CONDITION THAT IS RESPONSIBLE for approximately 1 in 200 emergency department visits in the United States.<sup>1</sup> It has an estimated lifetime prevalence of 60% in the general U.S. population, and approximately 6% of persons who have nosebleeds seek medical attention.<sup>2</sup> Management of this condition is straightforward in most cases but can be difficult in patients with cardiovascular disease, impaired coagulation, or platelet dysfunction.

In most cases, bleeding starts spontaneously, without any obvious precipitant. The underlying causes of and risk factors for epistaxis are classified as being local (e.g., lack of humidification, trauma, intranasal medication application, infection, inflammation, and tumors), systemic (e.g., blood dyscrasias, leukemia, atherosclerosis, hypertension, and congestive heart failure), or idiopathic. Recurrent epistaxis may be the first sign of systemic or local neoplastic disease. Hereditary hemorrhagic telangiectasia — an autosomal dominant vascular disorder that has a prevalence of 1 in 5000 persons and that is characterized by mucocutaneous telangiectasias and systemic arteriovenous malformations<sup>3</sup> — commonly manifests as spontaneous, recurrent epistaxis,<sup>4</sup> which can be functionally and socially debilitating.<sup>5</sup>

The nose is well vascularized, with arteries that originate from branches of the internal carotid and external carotid arteries (Fig. 1). Approximately 80 to 90% of epistaxis events occur in the anterior nasal cavity, typically from the antero-inferior septum in Little's area, where the Kiesselbach plexus is found.<sup>6</sup> This plexus is a rich confluence of vessels from the internal carotid (anterior ethmoidal) and external carotid (sphenopalatine, greater palatine, and superior labial) arteries.<sup>7</sup> Anterior bleeding events are the most common types of epistaxis, are usually easy to control, and pose a minimal risk of airway compromise or aspiration. Approximately 10 to 20% of cases of epistaxis are attributable to posterior bleeding events that arise from branches of the sphenopalatine and ascending pharyngeal arteries.<sup>8</sup> Such cases of epistaxis are usually located on the posterior septum (in 67% of patients), the lateral nasal wall (in 25%), or the nasal floor (in 8%).<sup>9</sup> Posterior bleeding events

## KEY CLINICAL POINTS

## EPISTAXIS

- Epistaxis is common, with an estimated lifetime prevalence in the United States of 60%. Approximately 6% of persons who have nosebleeds seek medical attention.
- The management of epistaxis is straightforward in most cases but can be challenging in patients with cardiovascular disease, impaired coagulation, or platelet dysfunction.
- Epistaxis is appropriately controlled in a systematic and escalating fashion. Initially, patients in the medical setting are advised to apply digital compression to the lower third of the nose for 15 to 20 minutes, which is followed by anterior rhinoscopy.
- Anterior bleeding can usually be controlled with topical vasoconstrictors, tranexamic acid, cautery, or anterior nasal packing.
- Continued epistaxis despite these measures requires more aggressive treatment, with the involvement of specialists in otolaryngology and head and neck surgery and, generally, hospital admission.

are more profuse and harder to control than anterior bleeding events, and they pose a greater risk of airway compromise or aspiration.

## STRATEGIES AND EVIDENCE

## EVALUATION

The evaluation of patients with epistaxis should be performed under blood (and other body fluid) precautions. Clinicians should follow their local guidelines for the use of personal protective equipment; these precautions generally include a non-water-permeable gown, protective eyewear, gloves, and a face mask. The required specialized medical equipment and materials are shown in Figure S1 in the Supplementary Appendix, available with the full text of this article at NEJM.org.

Initial treatment of a patient with epistaxis is guided by the assessment of the airway and hemodynamic variables. Airway compromise or hemorrhagic shock from epistaxis is rare but is an important consideration in patients who are bleeding from both nares or the mouth or who have hemodynamic instability, syncope, skin pallor, diaphoresis, or cool arms and legs. In patients with the majority of these findings, immediate securing of the airway and resuscitation are necessary.

A directed history and a cursory physical examination, including vital signs, should be performed while the patient digitally compresses the lower nares (see the Treatment section below). History-taking should involve attention to the quantity and frequency of bleeding, history of nasal or facial trauma, other sites of bleeding or bruising, history of nasal surgery, coexisting conditions, current medications, and family his-

tory of bleeding. After compression, anterior rhinoscopy is performed with the use of a nasal speculum and a headlight.

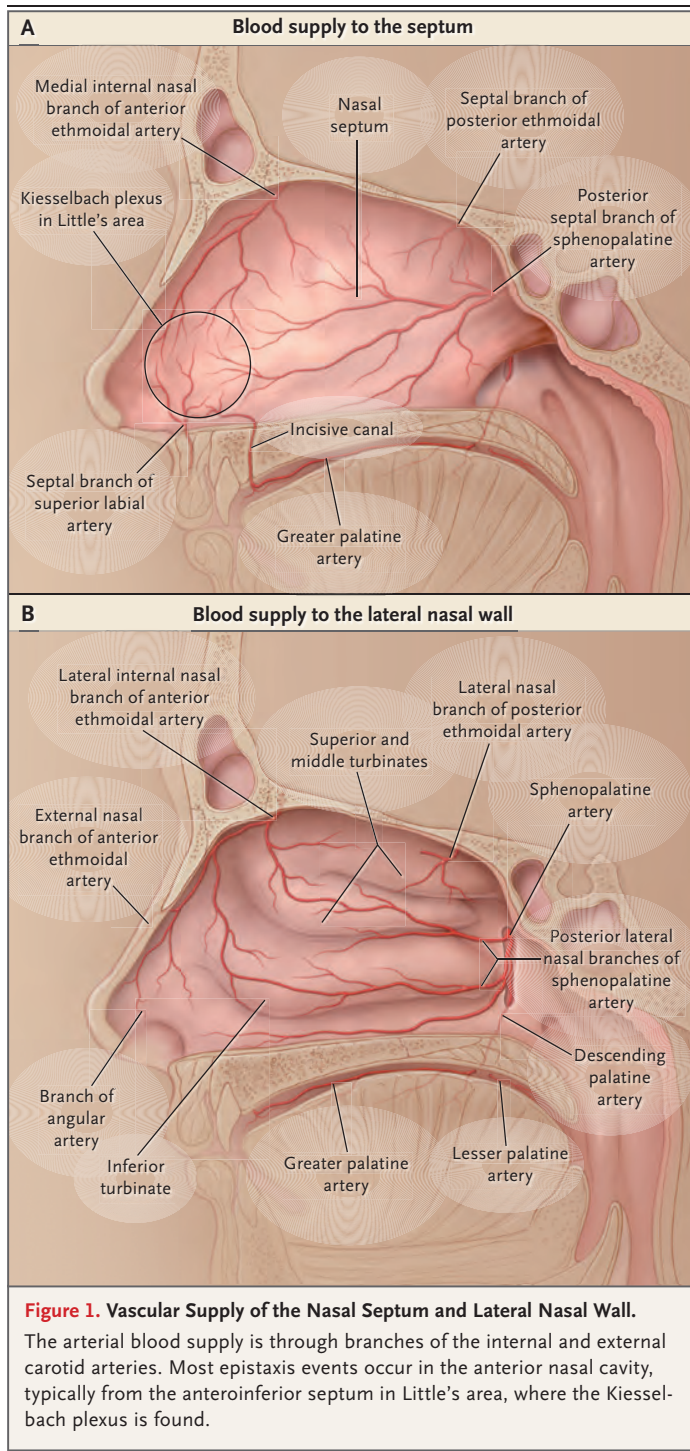
## TREATMENT

Epistaxis is appropriately controlled in a systematic and escalating fashion. Initially, patients in the medical setting are advised to apply continuous digital compression to the lower third of the nose for 15 to 20 minutes while leaning forward (Fig. 2).<sup>10</sup> This action helps to achieve tamponade of the anterior nasal blood vessels while preventing aspiration, swallowing of blood, and airway compromise.

Anterior rhinoscopy is performed after digital compression. If the bleeding continues and a site of bleeding is identified, topical vasoconstrictors or cauterization are used. If the bleeding site is not identified or if profuse bleeding precludes the identification of a distinct site, the anterior part of the nose is packed (see below). Control of bleeding with these maneuvers occurs in nearly all patients with anterior bleeding events. Patients can then be discharged from care with appropriate follow-up and education.<sup>11</sup> In patients who continue to bleed, more aggressive salvage measures are needed, usually with the involvement of a specialist in otolaryngology and head and neck surgery and, generally, with hospital admission.

## VASOCONSTRICTORS

Topical vasoconstricting agents such as oxymetazoline, phenylephrine, epinephrine, or cocaine may be used to manage epistaxis, but data regarding their effectiveness are limited. Treatment with oxymetazoline, a selective  $\alpha_1$ -adrenergic-receptor agonist and  $\alpha_2$ -adrenergic-receptor partial agonist,



is preferred in the context of outpatient or ambulatory care. A double-blind, randomized, controlled trial of prevention of epistaxis associated with nasotracheal intubation showed that oxymetazo-

line was as effective as cocaine (86% and 57% of patients, respectively) and more effective than lidocaine with epinephrine (29%).<sup>12</sup>

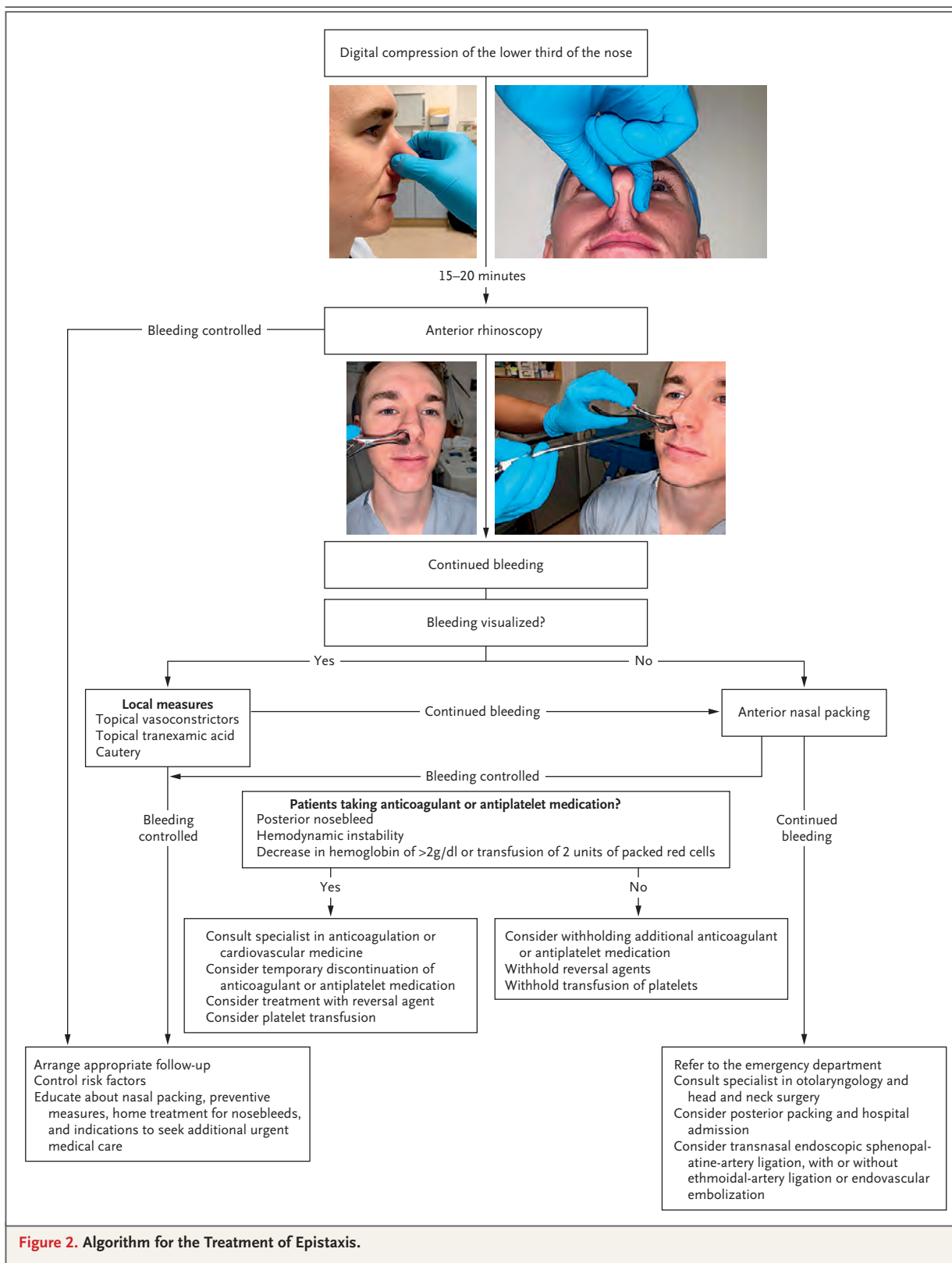
The use of topical vasoconstrictors may be associated with an increased risk of cardiac or other systemic complications.<sup>11</sup> A randomized, double-blind, placebo-controlled trial involving patients without hypertension or cardiovascular disease showed no significant differences, as compared with saline, in the mean arterial pressure with intranasal application of oxymetazoline 0.05%, phenylephrine 0.25%, or lidocaine 1% with epinephrine 1:100,000.<sup>13</sup> However, there are case reports of patients in whom acute coronary syndrome developed after the use of nasal oxymetazoline.<sup>14,15</sup> Thus, caution is warranted regarding the use of these agents in patients with hypertension or coronary disease.

#### TRANEXAMIC ACID

Tranexamic acid is an antifibrinolytic agent that can be administered orally or, more commonly, topically to control epistaxis. A Cochrane review<sup>16</sup> showed moderate-quality evidence of a lower risk of recurrent bleeding within 10 days with oral or topical tranexamic acid than with placebo (47% vs. 67%; risk ratio, 0.71; 95% confidence interval [CI], 0.56 to 0.90); the single trial of topical tranexamic acid was small and did not show a significantly lower risk of recurrent bleeding than that with placebo (risk ratio, 0.66; 95% CI, 0.41 to 1.05), but the estimated risk was similar to that seen in the two trials of oral tranexamic acid. Moreover, pooled data from three additional trials provided moderate-quality evidence of a greater frequency of hemostasis in the first 10 minutes after use of topical tranexamic acid than with other topical agents.<sup>16</sup>

#### CAUTERIZATION

When the bleeding site is identified, cauterization is attempted. If possible, a topical anesthetic is applied. Cauterization can be performed by means of topical application chemicals, such as silver nitrate, or electrical energy. A systematic review largely involving prospective observational studies concluded that electrocautery was associated with greater efficacy than chemical cautery (failure in 14.5% of patients vs. 35.1%) without a higher incidence of complications or discomfort.<sup>17</sup> Both methods of cauterization require good visualization and a relatively bloodless surface, which





may be achieved with the use of suction, a nasal speculum, and headlight. Complications include nasal crusting and infection<sup>17</sup>; septal perforation is rare, and the risk is minimized by avoidance of cauterization of both sides of the septum.

#### ANTERIOR NASAL PACKING

Nasal packing reduces bleeding by means of direct physical pressure on the mucosa or activation of the clotting cascade. Packing materials are either resorbable or nonresorbable (requiring removal) (Table S1). Insertion of materials is performed along a horizontal plane, following the trajectory of the nasal floor, and it is important to adhere to the details of the manufacturer instructions. Contraindications to nasal packing include clinically significant facial or nasal bone fractures or basilar skull fractures.<sup>18</sup> Complications of nasal packing are rare and include nasal obstruction, septal perforations, posterior dislodgement, aspiration, eustachian-tube dysfunction, obstructive sleep apnea, foreign-body reactions, and toxic shock syndrome.<sup>19</sup>

##### *Resorbable Packing*

Resorbable packing is generally preferred over nonresorbable packing, especially in patients with a suspected bleeding disorder or those using anticoagulants or antiplatelet medications. Resorbable packing material is more comfortable during insertion and avoids the prolonged recurrent bleeding from the irritated nasal mucosa associated with the removal of packing material, but it may be more costly. Failure to control bleeding with this packing may result in the advancement to treatment with nonresorbable packing. Resorbable packs are classified into the following categories: extracellular matrix-based biomaterials, coagulation-cascade precipitants, and natural and synthetic biopolymers.<sup>19</sup>

Extracellular matrix-based biomaterials are derived from collagen or hyaluronic acid and can effect hemostasis by means of tamponade or activation of the coagulation cascade if augmented with thrombin. Floseal (Baxter), a flowable compound mixture made of bovine-derived, granulated gelatin matrix and human-derived thrombin, has been reported in observational studies and randomized trials to lead to treatment success in 75 to 90% of patients, with hemostasis ranging from 2 to 14 days.<sup>20-24</sup> Randomized,

controlled trials have shown that treatment with Floseal has efficacy similar to that with traditional packing in controlling acute anterior epistaxis and that it results in less patient discomfort at initial control of epistaxis and at 48-hour and 7-day follow-up.<sup>23,25</sup>

Fibrin sealants are coagulation-cascade precipitants that have been developed from purified human-origin cryoprecipitate and thrombin. In an observational study, a fibrin sealant (Quixil, Omrix Biopharmaceuticals) was associated with rapid hemostasis and with a greater reduction in local edema, mucosal atrophy, and nasal discharge than was observed with electrocautery, silver nitrate, and nonresorbable packing material.<sup>26</sup>

Nasopore, a freeze-dried polyurethane foam, is one of two purely synthetic absorbable biomaterials on the market. Although data are limited regarding the use of this freeze-dried polyurethane foam in patients with acute epistaxis, its usefulness in achieving hemostasis after nasal surgery has been well documented.<sup>27-31</sup> A meta-analysis of seven randomized trials showed that the use of Nasopore after nasal surgery led to a significantly greater reduction in patient discomfort and bleeding than nonresorbable packing material (Merocelel).<sup>32</sup>

##### *Nonresorbable Packing*

Innovations in nonresorbable packing have outgrown the traditional layered insertion of petroleum jelly-impregnated ribbon gauze. Commonly used devices are the expandable polyvinyl acetate foam tampons (Merocelel, Medtronic Xomed) and fabric sponges coated with carboxymethylcellulose, which facilitates insertion and removal (Rapid Rhino Riemann, Applied Therapeutics).

Two randomized, controlled trials comparing the polyvinyl acetate foam tampons with the carboxymethylcellulose-coated sponges showed no significant differences in hemostasis (bleeding controlled in 81% vs. 76% of patients and in 72% vs. 76%).<sup>33,34</sup> However, packing with the carboxymethylcellulose-coated sponges resulted in significantly less patient discomfort during insertion and removal.<sup>33,34</sup>

The duration of packing typically ranges from 48 to 72 hours. Nonresorbable packing materials can cause substantial pain on insertion, while in place, and during removal.

**SALVAGE BLEEDING CONTROL**

When bleeding continues despite the above procedures, treatment options include posterior packing, arterial ligations, and endovascular embolization. The choice among these is often guided by local expertise.

**POSTERIOR PACKING**

Posterior packs occlude the posterior choana with gauze, a Foley catheter, or an inflatable nasal balloon catheter, and, in conjunction with nonresorbable anterior nasal packs, they secure tamponade of the nasal cavity and provide hemostasis. Posterior packing is very uncomfortable and is associated with a higher risk of complications (e.g., otitis media, sinusitis, necrosis of nasal tissues, airway obstruction, hypoxemia due to stimulation of the nasopulmonary reflex, and toxic shock syndrome) than anterior packing.<sup>35</sup>

**LIGATION AND ENDOVASCULAR EMBOLIZATION**

In cases when appropriate expertise is available, arterial ligation or embolization can be used for persistent or recurrent epistaxis that is refractory to initial treatments, with the goal of occluding the source of bleeding while preserving sinonasal function. Transnasal endoscopic sphenopalatine-artery ligation and ethmoidal-artery ligation (with the use of clipping or electrocauterization of the sphenopalatine and ethmoidal arteries) is effective for intractable epistaxis, with low rates of failure and complications. In a review of 11 case series involving 127 patients, the mean percentage of patients with treatment success was 98%.<sup>36</sup> In a meta-analysis of 896 cases, recurrent bleeding occurred in 13.4% of the patients and was attributable to anatomical variations and incomplete arterial occlusion; complications (including nasal crusting, dryness, and acute sinusitis) occurred in 8.7% of the patients.<sup>37</sup>

Arterial embolization, performed by means of interventional radiology, occludes blood flow in the terminal branches of the external carotid artery. Minor transient complications (facial pain, facial numbness, and altered mental status) have been reported in 25 to 59% of patients.<sup>38</sup> Serious complications are uncommon (in <2% of patients) but include cerebrovascular accidents, hemiplegia, ophthalmoplegia, facial-nerve palsy, seizures, and soft-tissue necrosis. Diagnostic angiography preceding embolization may reveal anatomical anomalies, anastomoses, or an unsuspected cause of

epistaxis (e.g., abnormal communication among the internal carotid, external carotid, or ophthalmic arteries).<sup>38</sup>

A retrospective study comparing ligation with embolization showed similar results, with 75% of the patients in each group having treatment success at 1 year and a similar overall incidence of complications in the two groups; however, the complications observed with embolization were more serious than those observed with ligation.<sup>38,39</sup> An economic evaluation suggested that sphenopalatine-artery ligation is more cost-effective than embolization.<sup>40</sup> Thus, embolization should be used only after arterial ligation has been unsuccessful or when arterial ligation is not feasible owing to abnormal vascular anatomy.

**TREATMENT OF PATIENTS TAKING ANTICOAGULANT AND ANTIPLATELET MEDICATIONS**

Patients who are taking anticoagulant or antiplatelet medications (or both) are more likely than persons not taking these medications to present with recurrent epistaxis and clinically significant blood loss (>250 ml) leading to blood transfusion.<sup>41</sup> The initial local management of epistaxis does not differ in these patients, but additional doses of anticoagulants or antiplatelet agents should be withheld during active bleeding. The reversal of anticoagulation or the transfusion of platelets, respectively, should be considered only in consultation with an appropriate medical specialist if the bleeding is severe (Fig. 2).<sup>42</sup>

**PATIENT EDUCATION**

At discharge, it is important to educate patients about indications to seek additional care, preventative measures, and home treatments for epistaxis. Nonresorbable packing material needs to be removed after 48 to 72 hours, and in patients with resorbable packing, follow-up within 1 week is necessary for the removal of any residual packing material. All patients should be monitored for proper healing of nasal mucosa, and patients should avoid nose blowing, strenuous activity, heavy lifting, and digital manipulation (nose picking) for at least 1 week.

Clinical experience indicates that the risk of recurrence can be minimized by the elimination of contributing factors such as digital manipulation and vigorous nose blowing and by using proper nasal hygiene, such as moisturizing and lubricating with nasal saline and gels. A humidi-

fier may also be beneficial. If epistaxis recurs, patients should lean forward and continuously pinch the lower third of the nose for 15 to 20 minutes and return for medical attention if bleeding is severe or persistent.

#### AREAS OF UNCERTAINTY

Whether systemic antibiotic agents should be prescribed for the prevention of local infection and toxic shock syndrome while nasal packs are in place is controversial. A systematic review of observational studies and randomized, controlled trials did not show a benefit of antibiotic therapy, but conclusions were limited by the low incidence of serious infection and by methodologic limitations of the included studies.<sup>43,44</sup>

A meta-analysis showed a significantly elevated risk of epistaxis among patients with hypertension (odds ratio vs. the risk among patients without hypertension, 1.53; 95% CI, 1.18 to 1.99), but it is uncertain whether this relationship is causal.<sup>45</sup> Data about guidance regarding blood-pressure management in patients with epistaxis are limited.<sup>46</sup>

#### GUIDELINES

The American Academy of Otolaryngology–Head and Neck Surgery published a clinical practice guideline for the evaluation and management of epistaxis in 2020.<sup>11</sup> The American College of Cardiology published an expert consensus decision pathway regarding the management of bleeding, including epistaxis, in patients taking oral anticoagulants in 2017.<sup>42</sup> The current recommendations are consistent with these guidelines.

#### CONCLUSIONS AND RECOMMENDATIONS

The patient described in the vignette has an acute episode of epistaxis and is clinically stable. Digital compression should be applied for 15 to 20 minutes and anterior rhinoscopy performed. If a bleeding site is identified, electrocautery, performed while the patient is under local anesthesia, is indicated. Owing to the patient's cardiovascular history, I would avoid the use of topical vasoconstrictors. If bleeding persisted, I would proceed with resorbable nasal packing, which is more comfortable than nonresorbable packing and eliminates the risk of prolonged recurrent bleeding after the removal of packing material (a particular concern given the patient's use of warfarin). I would consider the use of nonresorbable packing material if bleeding continued. In consultation with a medical specialist, I would consider advising the patient to discontinue warfarin temporarily. Posterior packing, arterial ligation, or embolization would be considerations for treatment if epistaxis continued despite the above measures. At discharge, it will be important to educate the patient about indications to seek additional care, preventative measures, and home treatments for epistaxis.

No potential conflict of interest relevant to this article was reported.

Disclosure forms provided by the author are available with the full text of this article at NEJM.org.

I thank Shanmugappiriya Sivarajah, M.D., M.P.H. (of the Division of Otolaryngology–Head and Neck Surgery, University of Alberta, Edmonton, Canada), and Kelvin Zhou, B.Sc. (of the Michael G. DeGroote School of Medicine, McMaster University, Hamilton, Ontario, Canada), for contributions to an earlier version of the manuscript.

#### REFERENCES

- Pallin DJ, Chng Y-M, McKay MP, Emond JA, Pelletier AJ, Camargo CA Jr. Epidemiology of epistaxis in US emergency departments, 1992 to 2001. *Ann Emerg Med* 2005;46:77-81.
- Chaaban MR, Zhang D, Resto V, Goodwin JS. Demographic, seasonal, and geographic differences in emergency department visits for epistaxis. *Otolaryngol Head Neck Surg* 2017;156:81-6.
- Faughnan ME, Palda VA, Garcia-Tsao G, et al. International guidelines for the diagnosis and management of hereditary haemorrhagic telangiectasia. *J Med Genet* 2011;48:73-87.
- Sautter NB, Smith TL. Treatment of hereditary hemorrhagic telangiectasia-related epistaxis. *Otolaryngol Clin North Am* 2016;49:639-54.
- Lennox PA, Hitchings AE, Lund VJ, Howard DJ. The SF-36 health status questionnaire in assessing patients with epistaxis secondary to hereditary hemorrhagic telangiectasia. *Am J Rhinol* 2005;19:71-4.
- Viehweg TL, Roberson JB, Hudson JW. Epistaxis: diagnosis and treatment. *J Oral Maxillofac Surg* 2006;64:511-8.
- Chiu T, Dunn JS. An anatomical study of the arteries of the anterior nasal septum. *Otolaryngol Head Neck Surg* 2006;134:33-6.
- Thornton MA, Mahesh BN, Lang J. Posterior epistaxis: identification of common bleeding sites. *Laryngoscope* 2005;115:588-90.
- McGarry GW. Nasal endoscope in posterior epistaxis: a preliminary evaluation. *J Laryngol Otol* 1991;105:428-31.
- Beck R, Sorge M, Schneider A, Dietz A. Current approaches to epistaxis treatment in primary and secondary care. *Dtsch Arztebl Int* 2018;115:12-22.
- Tunkel DE, Anne S, Payne SC, et al. Clinical practice guideline: nosebleed (epistaxis). *Otolaryngol Head Neck Surg* 2020;162:Suppl 1:S1-S38.

12. Katz RI, Hovagim AR, Finkelstein HS, Grinberg Y, Boccio RV, Poppers PJ. A comparison of cocaine, lidocaine with epinephrine, and oxymetazoline for prevention of epistaxis on nasotracheal intubation. *J Clin Anesth* 1990;2:16-20.
13. Bellew SD, Johnson KL, Nichols MD, Kummer T. Effect of intranasal vasoconstrictors on blood pressure: a randomized, double-blind, placebo-controlled trial. *J Emerg Med* 2018;55:455-64.
14. Montastruc F, Montastruc G, Taudou M-J, Olivier-Abbal P, Montastruc J-L, Bondon-Guitton E. Acute coronary syndrome after nasal spray of oxymetazoline. *Chest* 2014;146(6):e214-e215.
15. Rajpal S, Morris LA, Akkus NI. Non-ST-elevation myocardial infarction with the use of oxymetazoline nasal spray. *Rev Port Cardiol* 2014;33(1):51.e1-51.e4.
16. Joseph J, Martinez-Devesa P, Bellorini J, Burton MJ. Tranexamic acid for patients with nasal haemorrhage (epistaxis). *Cochrane Database Syst Rev* 2018;12:CD004328.
17. McLeod RWJ, Price A, Williams RJ, Smith ME, Smith M, Owens D. Intranasal cautery for the management of adult epistaxis: systematic review. *J Laryngol Otol* 2017;131:1056-64.
18. Kravchik L, Jamal Z, Pester JM. Anterior epistaxis nasal pack. Treasure Island, FL: StatPearls Publishing, 2020 (<http://www.ncbi.nlm.nih.gov/pubmed/30855888>).
19. Massey CJ, Suh JD, Tessema B, Gray ST, Singh A. Biomaterials in rhinology. *Otolaryngol Head Neck Surg* 2016;154:606-17.
20. Lau AS, Upile NS, Lazarova L, Swift AC. Evaluating the use of FloSeal hemostatic matrix in the treatment of epistaxis: a prospective, control-matched longitudinal study. *Eur Arch Otorhinolaryngol* 2016;273:2579-84.
21. Wakelam OC, Dimitriadis PA, Stephens J. The use of FloSeal hemostatic sealant in the management of epistaxis: a prospective clinical study and literature review. *Ann R Coll Surg Engl* 2017;99:28-30.
22. Kilty SJ, Al-Hajry M, Al-Mutairi D, et al. Prospective clinical trial of gelatin-thrombin matrix as first line treatment of posterior epistaxis. *Laryngoscope* 2014;124:38-42.
23. Murray S, Mendez A, Hopkins A, El-Hakim H, Jeffery CC, Côté DWJ. Management of persistent epistaxis using FloSeal Hemostatic Matrix vs. traditional nasal packing: a prospective randomized controlled trial. *J Otolaryngol Head Neck Surg* 2018;47:3.
24. Côté D, Barber B, Diamond C, Wright E. FloSeal hemostatic matrix in persistent epistaxis: prospective clinical trial. *J Otolaryngol Head Neck Surg* 2010;39:304-8.
25. Mathiasen RA, Cruz RM. Prospective, randomized, controlled clinical trial of a novel matrix hemostatic sealant in patients with acute anterior epistaxis. *Laryngoscope* 2005;115:899-902.
26. Vaiman M, Segal S, Eviatar E. Fibrin glue treatment for epistaxis. *Rhinology* 2002;40:88-91.
27. Yilmaz MS, Guven M, Elicora SS, Kaymaz R. An evaluation of biodegradable synthetic polyurethane foam in patients following septoplasty: a prospective randomized trial. *Otolaryngol Head Neck Surg* 2013;148:140-4.
28. Kim YS, Kim YH, Kim NH, Kim SH, Kim KR, Kim K-S. A prospective, randomized, single-blinded controlled trial on biodegradable synthetic polyurethane foam as a packing material after septoplasty. *Am J Rhinol Allergy* 2011;25(2):e77-e79.
29. Jang SY, Lee KH, Lee SY, Yoon JS. Effects of nasopore packing on dacryocystorhinostomy. *Korean J Ophthalmol* 2013;27:73-80.
30. Shoman N, Gheriani H, Flamer D, Javer A. Prospective, double-blind, randomized trial evaluating patient satisfaction, bleeding, and wound healing using biodegradable synthetic polyurethane foam (NasoPore) as a middle meatal spacer in functional endoscopic sinus surgery. *J Otolaryngol Head Neck Surg* 2009;38:112-8.
31. Jung MS, Choi CH, Yu MS. Comparison of the effect of aerosolized fibrin sealant and biodegradable synthetic polyurethane foam on hemostasis and wound healing after endoscopic sinus surgery: a prospective randomized study. *Int Forum Allergy Rhinol* 2017;7:1089-94.
32. Wang J, Cai C, Wang S. Merocel versus Nasopore for nasal packing: a meta-analysis of randomized controlled trials. *PLoS One* 2014;9(4):e93959.
33. Moumoulidis I, Draper MR, Patel H, Jani P, Price T. A prospective randomised controlled trial comparing Merocel and Rapid Rhino nasal tampons in the treatment of epistaxis. *Eur Arch Otorhinolaryngol* 2006;263:719-22.
34. Badran K, Malik TH, Belloso A, Timms MS. Randomized controlled trial comparing Merocel and Rapid Rhino packing in the management of anterior epistaxis. *Clin Otolaryngol* 2005;30:333-7.
35. Vidulich RA, Blanda MP, Gerson LW. Posterior epistaxis: clinical features and acute complications. *Ann Emerg Med* 1995;25:592-6.
36. Kumar S, Shetty A, Rockey J, Nilssen E. Contemporary surgical treatment of epistaxis: what is the evidence for sphenopalatine artery ligation? *Clin Otolaryngol Allied Sci* 2003;28:360-3.
37. Kitamura T, Takenaka Y, Takeda K, et al. Sphenopalatine artery surgery for refractory idiopathic epistaxis: systematic review and meta-analysis. *Laryngoscope* 2019;129:1731-6.
38. Willems PWA, Farb RI, Agid R. Endovascular treatment of epistaxis. *AJNR Am J Neuroradiol* 2009;30:1637-45.
39. de Bonnecaze G, Gallois Y, Bonneville F, Vergez S, Chaput B, Serrano E. Transnasal endoscopic sphenopalatine artery ligation compared with embolization for intractable epistaxis: a long-term analysis. *Am J Rhinol Allergy* 2018;32:188-93.
40. Rudmik L, Leung R. Cost-effectiveness analysis of endoscopic sphenopalatine artery ligation vs arterial embolization for intractable epistaxis. *JAMA Otolaryngol Head Neck Surg* 2014;140:802-8.
41. Musgrave KM, Powell J. A systematic review of anti-thrombotic therapy in epistaxis. *Rhinology* 2016;54:292-391.
42. Tomaselli GF, Mahaffey KW, Cuker A, et al. 2017 ACC expert consensus decision pathway on management of bleeding in patients on oral anticoagulants: a report of the American College of Cardiology Task Force on Expert Consensus Decision Pathways. *J Am Coll Cardiol* 2017;70:3042-67.
43. Cohn B. Are prophylactic antibiotics necessary for anterior nasal packing in epistaxis? *Ann Emerg Med* 2015;65:109-11.
44. Lange JL, Peeden EH, Stringer SP. Are prophylactic systemic antibiotics necessary with nasal packing? A systematic review. *Am J Rhinol Allergy* 2017;31:240-7.
45. Min HJ, Kang H, Choi GJ, Kim KS. Association between hypertension and epistaxis: systematic review and meta-analysis. *Otolaryngol Head Neck Surg* 2017;157:921-7.
46. Payne SC, Feldstein D, Anne S, Tunkel DE. Hypertension and epistaxis: why is there limited guidance in the nosebleed clinical practice guidelines? *Otolaryngol Head Neck Surg* 2020;162:33-4.

Copyright © 2021 Massachusetts Medical Society.