

VIDEOS IN CLINICAL MEDICINE
SUMMARY POINTS

Julie R. Ingelfinger, M.D., *Editor*

Focused Cardiac Ultrasonography for Right Ventricular Size and Systolic Function

Gabriel Prada, M.D., Aliaksei Pustavoitau, M.D., M.H.S., Seth Koenig, M.D.,
Carol Mitchell, Ph.D., Raymond F. Stainback, M.D.,
and Jos L. Diaz-Gomez, M.D.

The following text summarizes information provided in the video.

OVERVIEW

Focused cardiac ultrasonography is a practical, transthoracic, qualitative or semi-quantitative means of assessing cardiac size, structure, and function that is performed and interpreted by the clinician at the bedside. Although the left ventricle has historically been the focus of echocardiographic assessment, the right ventricle is increasingly being recognized as having equal importance in the assessment of acute and chronic cardiovascular and pulmonary diseases. This video presents a practical method for conducting visual, semiquantitative assessment of right ventricular size and systolic function with focused cardiac ultrasonography.

INDICATIONS AND APPLICATIONS

Focused cardiac ultrasonography for right ventricular size and systolic function is indicated in patients with chest pain, dyspnea, arterial hypotension, unexplained tachycardia, hypoxemia, shock, acute respiratory failure, or cardiac arrest. Focused cardiac ultrasonography should not replace physical examination and often prompts the use of more advanced methods of evaluation, such as comprehensive echocardiography.

Echocardiographic evidence of right ventricular systolic dysfunction predicts worse morbidity and mortality in patients with chronic pulmonary diseases, acute pulmonary embolism, acute myocardial infarction, and left-sided heart failure.¹ In patients with pulmonary embolism, qualitative assessments of right ventricular size and systolic function are reliable and highly specific, and semiquantitative assessments can guide selection of hemodynamically stable patients for thrombolysis given improvements in morbidity and mortality.²⁻⁵ Right ventricular systolic dysfunction can manifest in critically ill patients who have shock or acute respiratory failure, including patients with conditions commonly related to the left ventricle (e.g., acute myocardial infarction and heart failure) and those more closely related to the right ventricle (e.g., chronic obstructive pulmonary disease and pulmonary hypertension).

The American Society of Echocardiography recommends that the evaluation of right ventricular systolic function consist of a qualitative assessment and at least one quantitative measure, such as cavity size of the right ventricle, the ratio of the right ventricle to the left ventricle with regard to end-diastolic diameter, fractional area change, systolic excursion of the tricuspid annular plane, and S' velocity with tissue Doppler echocardiographic imaging.¹ Although focused cardiac ultrasonog-

From Johns Hopkins Hospital, Baltimore (G.P., A.P.); Albert Einstein College of Medicine, New York (S.K.); the University of Wisconsin, Madison (C.M.); and Baylor College of Medicine, Houston (R.F.S., J.L.D.-G.). Dr. Diaz-Gomez can be contacted at Jose.Diaz-Gomez@bcm.edu or at the Department of Anesthesiology and Critical Care Medicine, Baylor College of Medicine, Houston, TX 77030.

N Engl J Med 2022;387:e52.

DOI: 10.1056/NEJMvcm2004089

Copyright © 2022 Massachusetts Medical Society.

raphy does not use quantitative measures, it does follow a systematic approach for a thorough visual assessment of right ventricular systolic function, whereby qualitative and semiquantitative measures appraise most components of the right ventricular systolic function that are classically addressed by quantitative measures with formal echocardiography. A survey of cardiologists, internists, intensivists, anesthesiologists, and emergency medicine physicians in 109 countries showed that visual assessment is the single most widely used method of estimating the right ventricular systolic function.⁶ Multiple studies indicate that most cases are detected by visual assessment, with excellent sensitivity (between 80% and 97%, although there is a tendency to overestimate the severity of abnormalities) and poor specificity (between 38% and 45%); the accuracy of visual assessment depends on operator experience.⁷⁻¹⁰ Further studies are needed to better validate visual assessment and elucidate its limitations. However, current evidence is reassuring and encouraging insofar as focused cardiac ultrasonography for right ventricular systolic function is predominantly used as a screening and early diagnostic tool intended to prompt the use and increase the yield of more advanced evaluations such as formal echocardiography, cardiac magnetic resonance imaging, and computed tomography.

ANATOMY

The right ventricle, the most anterior cardiac chamber, is located immediately beneath the sternum. Its walls are thinner than those of the left ventricle, with abundant trabeculae projecting from the inner surface. The right ventricular cavity is enclosed by the endocardial border (Fig. 1). On its apical (coronal) four-chamber plane, it has a triangular shape. On its short axis, it has the shape of a crescent as it wraps around the left ventricle.

RIGHT VENTRICULAR SYSTOLIC FUNCTION

The right ventricle is a low-pressure, high-volume system that can expand and contract to accommodate changes in blood volume. As a result, right ventricular systolic function depends heavily on preload conditions and is remarkably susceptible to sudden increases in afterload. Systolic function relies primarily on shortening of the muscle fibers along the longitudinal plane and secondarily on the radial thickening of the myocardium.

EQUIPMENT

Focused cardiac ultrasonography requires an ultrasound system with two-dimensional imaging, a transthoracic phased-array probe, ultrasound transmission gel, and a pair of gloves (Fig. 2).

PREPARATION

Before beginning the procedure, wash or sanitize your hands. Explain the procedure to the patient, and mention that the procedure is not associated with risks or complications. Put on a pair of gloves and expose the patient's thorax. Although imaging is optimally performed with the patient in the left lateral decubitus position, in many ill patients the only feasible option is to perform imaging with the patient in the supine position. The video shows the patient in the supine position.

ECHOCARDIOGRAPHIC VIEWS

The recommended echocardiographic views for the visual assessment of right ventricular size and systolic function are the standard apical four-chamber view, the apical four-chamber view with focus on the right ventricle (also referred to as

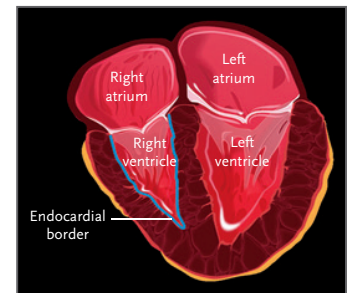


Figure 1. Anatomy of the Heart.

Shown is the heart in the apical four-chamber plane.

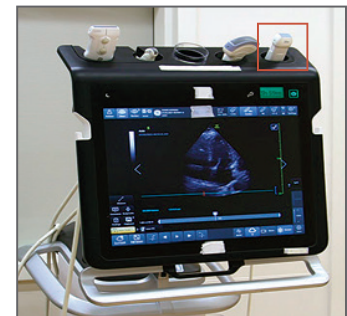

Figure 2. Ultrasound Machine with Phased-Array Probe.

The phased-array probe is shown inside the red square.

Table 1. Procurement of Echocardiographic Views.

View	Location of Probe	Approximate Orientation of Probe Marker	Depth (cm)	Tips
Standard apical four-chamber view	Point of maximal impulse*	3 o'clock position	15–20	Probe must be angled at 60 degrees relative to chest wall, facing toward right upper hemithorax. If atria are not visible, tilt the probe upward (the probe's tail will be down). If the left ventricular outflow tract is visible, tilt the probe downward (the probe's tail will be up).
Apical four-chamber view with focus on the right ventricle	Point of maximal impulse*	2 to 4 o'clock position	15–20	Find the standard apical four-chamber view. Keeping the left ventricle in the center of the image, rotate the probe counterclockwise to demonstrate the maximal size of the right ventricular cavity.
Parasternal short-axis view	Left third or fourth intercostal space, adjacent to the sternum	2 o'clock position	10–14	At midpapillary level, tilt the probe downward, toward the patient's left flank.

* As an alternative to placing the probe at the point of maximal impulse, start from the anterior axillary line at the left fifth or sixth intercostal space and move toward the nipple, using a zig-zag movement, until the heart is seen. In female patients, place the probe under the breast crease.

the right-ventricle focused apical four-chamber view), the parasternal short-axis view at the midpapillary level, and the subcostal four-chamber view (Table 1).

To obtain any of these echocardiographic views, set the field depth to 20 cm and then adjust the depth and gain to show structures of interest at their maximal size. To obtain an image in the standard apical four-chamber view, place the probe over the point of maximal impulse. Hold the probe at an angle of 60 degrees relative to the chest wall, facing the sternal notch, with the orientation marker pointing toward the 3 o'clock position. Optimize the image to see all four chambers of the heart: the left atrium, left ventricle, right atrium, and right ventricle.

To obtain an image in the apical four-chamber view with focus on the right ventricle, first find the standard apical four-chamber view. Then, keeping the left ventricle in the center of the image, rotate the probe counterclockwise to show the maximal size of the right ventricular cavity on the image.

To obtain an image in the parasternal short-axis view at the midpapillary level, place the probe over the third to fourth intercostal space, on the left side of the sternum. Hold the probe perpendicular to the chest wall or tilt it slightly toward the apex. The orientation marker should be pointing toward the 2 o'clock position or the patient's left shoulder. The papillary muscles of the left ventricle and the interventricular septum should be visible throughout the cardiac cycle (Fig. 3).

The subcostal four-chamber view should be routinely obtained. It is best performed with the patient in the supine position with the knees bent, to help relax the rectus abdominis muscles. This view is described in Figure S1 in the Supplementary Appendix, available with the video and the full text of this summary at NEJM.org.

ECHOCARDIOGRAPHIC MEASURES OF RIGHT VENTRICULAR SIZE AND SYSTOLIC FUNCTION

To evaluate right ventricular size and systolic function by means of focused cardiac ultrasonography, use the following measures: the cavity size of the right ventricle relative to that of the left ventricle, the shape of the interventricular septum, and McConnell's sign, which are measures of right ventricular loading; and

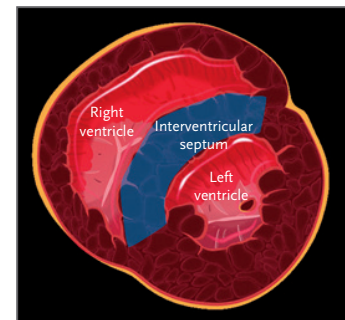


Figure 3. Short-Axis View of the Heart. In a cross-sectional view of the heart, the shape of the interventricular septum can be seen.

longitudinal shortening (which correlates with TAPSE [tricuspid annular plane systolic excursion], a quantitative measure of advanced echocardiography) and change in the area of the cavity, which are measures of contractility.

Cavity Size

Cavity size of the right ventricle relative to that of the left ventricle is evaluated in the standard apical four-chamber view. In each ventricle, the space enclosed by the endocardial border represents the area of the cavity. The diameter at the base of the cavity, measured immediately above the horizontal plane of the tricuspid annulus, can be used as a surrogate measurement in cases in which complete visualization of the right ventricular cavity is not possible and in cases in which the left ventricular cavity is enlarged or unusually small.

Measure each ventricular cavity at end diastole, when the cavity reaches its maximal size. In addition, identify the apex of the heart and assess whether it is formed mainly by the left ventricle or the right ventricle. When the size of the right ventricular cavity is less than or equal to two thirds the size of the left ventricular cavity and the left ventricle forms the apex of the heart, then the right ventricular cavity size is normal, which suggests normal preload and afterload conditions. When the size of the right ventricular cavity is equal to or greater than the size of the left ventricular cavity and the apex is formed by the right ventricle, then the right ventricular cavity is enlarged, which indicates excessively increased loading conditions.

Shape of the Interventricular Septum

The shape of the interventricular septum is evaluated in the parasternal short-axis view at the midpapillary level. When the shape of the interventricular septum is curved throughout the cardiac cycle, giving the left ventricular myocardium a circular shape, then right ventricular loading conditions are likely to be normal. When the interventricular septum becomes flat at times during the cardiac cycle, giving the left ventricular myocardium the shape of the letter D, then loading conditions are excessively increased.

Longitudinal Shortening

Longitudinal shortening is best evaluated in the standard apical four-chamber view. Longitudinal shortening is the semiquantitative version of TAPSE. Identify the segment between the base and the apex of the right side of the heart, which corresponds to the right ventricular longitudinal plane. The lateral tricuspid annulus can be used as an anatomical reference point.

The segment reaches its maximal length at end diastole. During systole, the segment shortens until it reaches its minimum length at end systole. The difference between the maximal length and the minimum length during the same cardiac cycle yields the estimated longitudinal shortening. A difference of at least 2 cm indicates normal right ventricular systolic function, whereas a difference of 1.5 cm or less suggests reduced function. Alternatively, in patients with normal left ventricular systolic function, longitudinal shortening can be evaluated by comparing right ventricular longitudinal shortening with left ventricular longitudinal shortening. When the longitudinal shortening of the right ventricle is at least twice that of the left ventricle, then right ventricular systolic function is normal, but when the longitudinal shortening of the right ventricle is equal to or less than that of the left ventricle, then function is likely to be reduced. Longitudinal shortening should also be evaluated in the apical four-chamber view with focus on the right ventricle.

Change in the Area of the Cavity

Change in the area of the cavity is best evaluated in the apical four-chamber view with focus on the right ventricle. The space enclosed by the endocardial border, excluding the papillary muscles and trabeculae, represents the area of the right ventricular cavity. The fractional decrease in the area of the cavity from end diastole to end systole during the same cardiac cycle yields the estimated change in the area of the cavity. A decrease of at least one third suggests normal right ventricular systolic function, whereas a decrease of less than one third suggests reduced function. The change in the area of the cavity should also be evaluated in the standard apical four-chamber view.

McConnell s Sign

McConnell s sign is described as regional right ventricular dysfunction with decreased or absent motion of the middle of the free wall but normal motion of the apex. McConnell s sign is a specific finding that can help to establish a diagnosis of acute right ventricular systolic dysfunction, often in patients with acute pulmonary embolism. However, McConnell s sign has very low sensitivity, and its absence should not be used to rule out acute right ventricular systolic dysfunction or acute pulmonary embolism.

PROCEDURE

Table 1 includes information on the procurement of echocardiographic views. To begin your evaluation of right ventricular size and systolic function, obtain images first in the standard apical four-chamber view, then in the apical four-chamber view with focus on the right ventricle, next in the parasternal short-axis view at the midpapillary level, and finally in the subcostal four-chamber view. (The video shows images from two patients: Patient 1 has normal right ventricular systolic function, and Patient 2 has severely reduced right ventricular systolic function; both patients have normal left ventricular systolic function.)

In the standard apical four-chamber view, identify the structures of interest, including the lateral tricuspid and mitral annuli, the apex, and the endocardial borders of the right and left ventricles. Evaluate the cavity size of the right ventricle relative to that of the left ventricle. In Patient 1, the size of the right ventricular cavity is less than two thirds the size of the left ventricular cavity and the apex is formed by the left ventricle. In Patient 2, the right ventricular cavity is larger than the left ventricular cavity and the apex is formed by the right ventricle. Next, evaluate longitudinal shortening. In Patient 1, longitudinal shortening of the right ventricle is at least 2 cm and at least twice the longitudinal shortening of the left ventricle, whereas in Patient 2, longitudinal shortening of the right ventricle is clearly less than 1.5 cm and less than that of the left ventricle. Finally, evaluate the change in the area of the cavity. In Patient 1, the area is decreased by at least one third, whereas in Patient 2, the area is decreased by less than one third.

The results for longitudinal shortening and for the change in the area of the cavity are similar in the apical four-chamber view with focus on the right ventricle and in the standard apical four-chamber view.

In the parasternal short-axis view at the midpapillary level, identify the structures of interest, including the interventricular septum and the left ventricular myocardium. In Patient 1, the interventricular septum is curved and the left ventricular myocardium has a circular shape throughout the cardiac cycle, whereas in Patient 2, the interventricular septum is flat and the left ventricular myocardium has a D shape throughout the cardiac cycle.

During the echocardiographic evaluation, it is essential to correlate and inte-

Table 2. Echocardiographic Measures of Right Ventricular Systolic Function.*

Right Ventricular Systolic Function	Loading Measures		Contractility Measures	
	Cavity Size of RV Relative to LV	Shape of Interventricular Septum	Longitudinal Shortening	Change in Area of Cavity
Normal	Cavity size less than or equal to two thirds of LV cavity size; apex formed by LV	Curved septum and circular LV myocardium	≥2 cm and at least twice that of LV	Decreased by at least one third
Severely reduced	Cavity size equal to or larger than LV cavity size; apex formed by RV	Flat septum and D-shaped LV myocardium	<1.5 cm and equal to or less than that of LV	Decreased by less than one third

* LV denotes left ventricle, and RV right ventricle.

Longitudinal shortening is a substitute for TAPSE (tricuspid annular plane systolic excursion, a quantitative measure of advanced echocardiography).

grate the information collected in each view to complete the assessment of each measure. The results for the two right ventricular loading measures can suggest but cannot confirm a definitive grading of systolic function as either normal or severely reduced. If both loading measures are normal, as in Patient 1, then right ventricular systolic function is likely to be adequate. In contrast, if at least one of the loading measures is abnormal, as in Patient 2, then right ventricular systolic function is possibly reduced. The results for the two right ventricular contractility measures can confirm the grading of systolic function as either normal or severely reduced. If both contractility measures are normal, as in Patient 1, then it is reasonable to grade the right ventricular systolic function as normal. In contrast, if both measures are abnormal, as in Patient 2, then it is reasonable to grade the right ventricular systolic function as severely reduced, especially if there are concomitant abnormal loading conditions (Table 2).

Right ventricular size and systolic function must be interpreted with respect to the chronicity of the disease state. Patients with chronic right ventricular systolic dysfunction, which is characterized by thickening of the right ventricular free wall on advanced echocardiography and by abnormal loading conditions, can present with normal contractility measures. In contrast, patients with acute right ventricular systolic dysfunction present with abnormal contractility measures, frequently accompanied by abnormal loading conditions, regardless of their previous right ventricular systolic function.

LIMITATIONS

The use of focused cardiac ultrasonography for the assessment of right ventricular size and systolic function may be limited by the level of operator competence in obtaining images of the right ventricle and by measure-related factors, such as incorrect inclusion of trabeculae or papillary muscles in the measurement of cavity size, regional wall-motion abnormalities, tricuspid-valve disease or replacement, or concomitant enlargement of the left ventricle and reduced left ventricular systolic function.

SUMMARY

In patients with suspected or known cardiovascular or pulmonary disease, focused cardiac ultrasonography can be used to evaluate right ventricular size and systolic function on the basis of four measures: the cavity size of the right ventricle relative to that of the left ventricle, the shape of the interventricular septum, longitudinal shortening, and change in the area of the cavity.

No potential conflict of interest relevant to this article was reported.
Disclosure forms provided by the authors are available with the full text of this article at NEJM.org.

REFERENCES

1. Rudski LG, Lai WW, Afilalo J, et al. Guidelines for the echocardiographic assessment of the right heart in adults: a report from the American Society of Echocardiography endorsed by the European Association of Echocardiography, a registered branch of the European Society of Cardiology, and the Canadian Society of Echocardiography. *J Am Soc Echocardiogr* 2010;23:685-713.
2. Weekes AJ, Oh L, Thacker G, et al. Interobserver and intraobserver agreement on qualitative assessments of right ventricular dysfunction with echocardiography in patients with pulmonary embolism. *J Ultrasound Med* 2016;35:2113-20.
3. Taylor RA, Moore CL. Accuracy of emergency physician-performed limited echocardiography for right ventricular strain. *Am J Emerg Med* 2014;32:371-4.
4. Dresden S, Mitchell P, Rahimi L, et al. Right ventricular dilatation on bedside echocardiography performed by emergency physicians aids in the diagnosis of pulmonary embolism. *Ann Emerg Med* 2014;63:16-24.
5. Kucher N, Boekstegers P, Moller OJ, et al. Randomized, controlled trial of ultrasound-assisted catheter-directed thrombolysis for acute intermediate-risk pulmonary embolism. *Circulation* 2014;129:479-86.
6. Schneider M, Aschauer S, Mascherbauer J, et al. Echocardiographic assessment of right ventricular function: current clinical practice. *Int J Cardiovasc Imaging* 2019;35:49-56.
7. Schneider M, Ran H, Aschauer S, et al. Visual assessment of right ventricular function by echocardiography: how good are we? *Int J Cardiovasc Imaging* 2019;35:2001-8.
8. Orde S, Slama M, Yastrebov K, Mclean A, Huang S; College of Intensive Care Medicine of Australia and New Zealand [CICM] Ultrasound Special Interest Group [USIG]. Subjective right ventricle assessment by echo qualified intensive care specialists: assessing agreement with objective measures. *Crit Care* 2019;23:70.
9. Ling LF, Obuchowski NA, Rodriguez L, Popovic Z, Kwon D, Marwick TH. Accuracy and interobserver concordance of echocardiographic assessment of right ventricular size and systolic function: a quality control exercise. *J Am Soc Echocardiogr* 2012;25:709-13.
10. Mjølstad OC, Dalen H, Graven T, Kleinau JO, Salvesen O, Haugen BO. Routinely adding ultrasound examinations by pocket-sized ultrasound devices improves inpatient diagnostics in a medical department. *Eur J Intern Med* 2012;23:185-91.

Copyright © 2022 Massachusetts Medical Society.